

ISUOG Practice Guidelines: performance of first-trimester fetal ultrasound scan

Clinical Standards Committee

The International Society of Ultrasound in Obstetrics and Gynecology (ISUOG) is a scientific organization that encourages safe clinical practice and high-quality teaching and research related to diagnostic imaging in women's healthcare. The ISUOG Clinical Standards Committee (CSC) has a remit to develop Practice Guidelines and Consensus Statements that provide healthcare practitioners with a consensus-based approach for diagnostic imaging. They are intended to reflect what is considered by ISUOG to be the best practice at the time at which they are issued. Although ISUOG has made every effort to ensure that Guidelines are accurate when issued, neither the Society nor any of its employees or members accept any liability for the consequences of any inaccurate or misleading data, opinions or statements issued by the CSC. The ISUOG CSC documents are not intended to establish a legal standard of care because interpretation of the evidence that underpins the Guidelines may be influenced by individual circumstances, local protocol and available resources. Approved Guidelines can be distributed freely with the permission of ISUOG (info@isuog.org).

INTRODUCTION

Routine ultrasound examination is an established part of antenatal care if resources are available and access possible. It is commonly performed in the second trimester¹, although routine scanning is offered increasingly during the first trimester, particularly in high-resource settings. Ongoing technological advancements, including high-frequency transvaginal scanning, have allowed the resolution of ultrasound imaging in the first trimester to evolve to a level at which early fetal development can be assessed and monitored in detail.

The aim of this document is to provide guidance for healthcare practitioners performing, or planning to perform, routine or indicated first-trimester fetal ultrasound scans. 'First trimester' here refers to a stage of pregnancy starting from the time at which viability can be confirmed (i.e. presence of a gestational sac in the uterine cavity with an embryo demonstrating cardiac activity) up to 13 + 6 weeks of gestation. Ultrasound scans performed after this

gestational age are not considered in these Guidelines. Throughout these Guidelines we use the term 'embryo' for before 10 weeks and 'fetus' thereafter, to reflect the fact that after 10 weeks of gestation organogenesis is essentially complete and further development involves predominantly fetal growth and organ maturation^{2,3}.

GENERAL CONSIDERATIONS

What is the purpose of a first-trimester fetal ultrasound scan?

In general, the main goal of a fetal ultrasound scan is to provide accurate information which will facilitate the delivery of optimized antenatal care with the best possible outcomes for mother and fetus. In early pregnancy, it is important to confirm viability, establish gestational age accurately, determine the number of fetuses and, in the presence of a multiple pregnancy, assess chorionicity and amnionicity. Towards the end of the first trimester, the scan also offers an opportunity to detect gross fetal abnormalities and, in health systems that offer first-trimester aneuploidy screening, measure the nuchal translucency thickness (NT). It is acknowledged, however, that many gross malformations may develop later in pregnancy or may not be detected even with appropriate equipment and in the most experienced of hands.

When should a first-trimester fetal ultrasound scan be performed?

There is no reason to offer routine ultrasound simply to confirm an ongoing early pregnancy in the absence of any clinical concerns, pathological symptoms or specific indications. It is advisable to offer the first ultrasound scan when gestational age is thought to be between 11 and 13 + 6 weeks' gestation, as this provides an opportunity to achieve the aims outlined above, i.e. confirm viability, establish gestational age accurately, determine the number of viable fetuses and, if requested, evaluate fetal gross anatomy and risk of aneuploidy^{4–20}. Before starting the examination, a healthcare provider should counsel the woman/couple regarding the potential benefits and limitations of the first-trimester ultrasound scan. (GOOD PRACTICE POINT)

Who should perform the first-trimester fetal ultrasound scan?

Individuals who perform obstetric scans routinely should have specialized training that is appropriate to the practice of diagnostic ultrasound for pregnant women. (GOOD PRACTICE POINT)

To achieve optimal results from routine ultrasound examinations it is suggested that scans should be performed by individuals who fulfill the following criteria:

1. have completed training in the use of diagnostic ultrasonography and related safety issues;
2. participate in continuing medical education activities;
3. have established appropriate care pathways for suspicious or abnormal findings;
4. participate in established quality assurance programs²¹.

What ultrasonographic equipment should be used?

It is recommended to use equipment with at least the following capabilities:

- real-time, gray-scale, two-dimensional (2D) ultrasound;
- transabdominal and transvaginal ultrasound transducers;
- adjustable acoustic power output controls with output display standards;
- freeze frame and zoom capabilities;
- electronic calipers;
- capacity to print/store images;
- regular maintenance and servicing.

How should the scan be documented?

An examination report should be produced as an electronic and/or paper document (see Appendix for an example). Such a document should be stored locally and, in accordance with local protocol, made available to the woman and referring healthcare provider. (GOOD PRACTICE POINT)

Is prenatal ultrasonography safe during the first trimester?

Fetal exposure times should be minimized, using the shortest scan times and lowest possible power output needed to obtain diagnostic information using the ALARA (As Low As Reasonably Achievable) principle. (GOOD PRACTICE POINT)

Many international professional bodies, including ISUOG, have reached a consensus that the use of B-mode and M-mode prenatal ultrasonography, due to its limited acoustic output, appears to be safe for all stages of pregnancy^{22,23}. Doppler ultrasound is, however, associated with greater energy output and therefore more potential bioeffects, especially when applied to a small region of interest^{24,25}. Doppler examinations should only be used in the first trimester, therefore, if clinically indicated. More details are available in the ISUOG Safety Statement²².

What if the examination cannot be performed in accordance with these Guidelines?

These Guidelines represent an international benchmark for the first-trimester fetal ultrasound scan, but consideration must be given to local circumstances and medical practices. If the examination cannot be completed in accordance with these Guidelines, it is advisable to document the reasons for this. In most circumstances, it will be appropriate to repeat the scan, or to refer to another healthcare practitioner. This should be done as soon as possible, to minimize unnecessary patient anxiety and any associated delay in achieving the desired goals of the initial examination. (GOOD PRACTICE POINT)

What should be done in case of multiple pregnancies?

Determination of chorionicity and amnionicity is important for care, testing and management of multifetal pregnancies. Chorionicity should be determined in early pregnancy, when characterization is most reliable^{26–28}. Once this is accomplished, further antenatal care, including the timing and frequency of ultrasound examinations, should be planned according to the available health resources and local guidelines. (GOOD PRACTICE POINT)

GUIDELINES FOR EXAMINATION

1. Assessment of viability/early pregnancy

In this Guideline, 'age' is expressed as menstrual or gestational age, which is 14 days more than conceptional age. Embryonic development visualized by ultrasound closely agrees with the 'developmental time schedule' of human embryos described in the Carnegie staging system³. The embryo is typically around 1–2 mm long when first detectable by ultrasound and increases in length by approximately 1 mm per day. The cephalic and caudal ends are indistinguishable until 53 days (around 12 mm), when the diamond-shaped rhombencephal cavity (future fourth ventricle) becomes visible¹⁸.

Defining viability

The term 'viability' implies the ability to live independently outside the uterus and, strictly speaking, cannot be applied to embryonic and early fetal life. However, this term has been accepted in ultrasound jargon to mean that the embryonic or fetal heart is seen to be active and this is taken to mean the conceptus is 'alive'. Fetal viability, from an ultrasound perspective, is therefore the term used to confirm the presence of an embryo with cardiac activity at the time of examination. Embryonic cardiac activity has been documented in normal pregnancies at as early as 37 days of gestation²⁹, which is when the embryonic heart tube starts to beat³⁰. Cardiac activity is often evident when the embryo measures 2 mm or more³¹, but is not evident in around 5–10% of viable embryos measuring between 2 and 4 mm^{32,33}.

Defining an intrauterine pregnancy

The presence of an intrauterine gestational sac clearly signifies that the pregnancy is intrauterine, but the criteria for the definition of a gestational sac are unclear. The use of terms such as an 'apparently empty' sac, the 'double-decidual ring' or even 'pseudosac' do not accurately confirm or refute the presence of an intrauterine pregnancy. Ultimately, the decision is a subjective one and is, therefore, influenced by the experience of the person performing the ultrasound examination. In an asymptomatic patient, it is advisable to wait until the embryo becomes visible within the intrauterine sac as this confirms that the 'sac' is indeed a gestational sac. (**GOOD PRACTICE POINT**)

2. Early pregnancy measurements

The mean gestational sac diameter (MSD) has been described in the first trimester from 35 days from the last menstrual period onwards. The MSD is the average of the three orthogonal measurements of the fluid-filled space within the gestational sac³⁴. Nomograms for both crown-rump length (CRL) and MSD are available, but, in the presence of the embryo, the CRL provides a more accurate estimation of gestational age because MSD values show greater variability of age prediction^{35,36}.

3. First-trimester fetal measurements

Which measurements should be performed in the first trimester?

CRL measurements can be carried out transabdominally or transvaginally. A midline sagittal section of the whole embryo or fetus should be obtained, ideally with the embryo or fetus oriented horizontally on the screen. An image should be magnified sufficiently to fill most of the width of the ultrasound screen, so that the measurement line between crown and rump is at about 90° to the ultrasound beam^{37,38}. Electronic linear calipers should be used to measure the fetus in a neutral position (i.e. neither flexed nor hyperextended). The end points of crown and rump should be defined clearly. Care must be taken to avoid inclusion of structures such as the yolk sac. In order to ensure that the fetus is not flexed, amniotic fluid should be visible between the fetal chin and chest (Figure 1). However, this may be difficult to achieve at earlier gestations (around 6–9 weeks) when the embryo is typically hyperflexed. In this situation, the actual measurement represents the neck-rump length, but it is still termed the CRL. In very early gestations it is not usually possible to distinguish between the cephalic and caudal ends and a greatest length measurement is taken instead.

The biparietal diameter (BPD) and head circumference (HC) are measured on the largest true symmetrical axial view of the fetal head, which should not be distorted by adjacent structures or transducer pressure. At about 10 weeks' gestation, structures such as the midline third ventricle, interhemispheric fissure and choroid

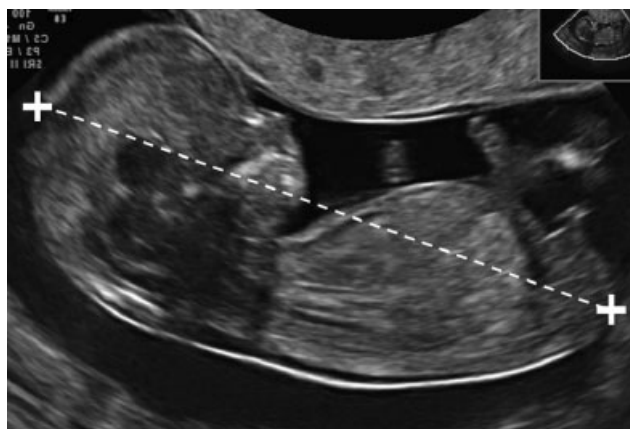


Figure 1 Crown-rump length (CRL) measurement technique in a fetus with CRL 60 mm (12 + 3 weeks). Note neutral position of neck.

plexuses should be visible. Towards 13 weeks, the thalamus and third ventricle provide good landmarks. Correct axial orientation is confirmed by including in the image both anterior horns and low occipital lobes of the cerebral ventricles, whilst keeping the plane above the cerebellum^{1,38–41}.

For BPD measurement, caliper placement should follow the technique used to produce the selected nomogram. Both outer-to-inner (leading edge) and outer-to-outer measurements are in use^{1,39,42,43} (Figure 2).

Other measurements

Nomograms are available for abdominal circumference (AC), femur length and most fetal organs, but there is no reason to measure these structures as part of the routine first-trimester scan.

4. Assessment of gestational age

Pregnant women should be offered an early ultrasound scan between 10 + 0 and 13 + 6 weeks to establish accurate gestational age. (**Grade A recommendation**)

Ultrasound assessment of embryonic/fetal age (dating) uses the following assumptions:

- gestational (menstrual age) represents post-conception age + 14 days;
- embryonic and fetal size correspond to post-conception (post fertilization) age;
- structures measured are normal;
- measurement technique conforms to the reference nomogram;
- measurements are reliable (both within and between observers);
- the ultrasound equipment is calibrated correctly.

Accurate dating is essential for appropriate follow-up of pregnancies and has been the primary indication for routine ultrasound in the first trimester. It provides valuable information for the optimal assessment of fetal

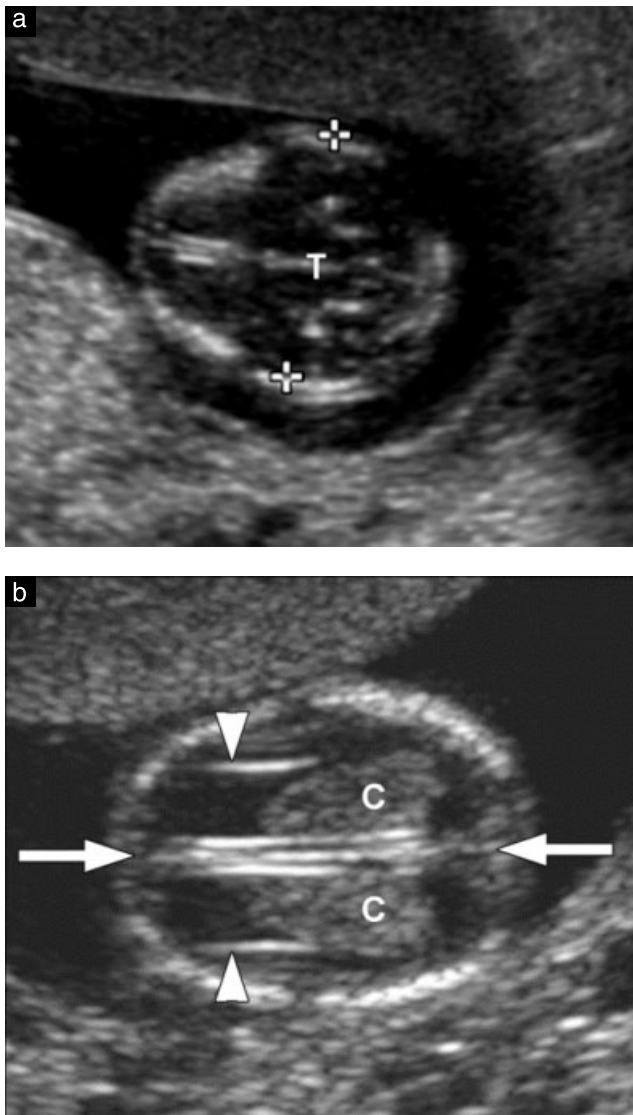


Figure 2 Fetal head. (a) Biparietal diameter (BPD) measurement (calipers). Note true axial view through head and central position of third ventricle and midline structures (T indicates third ventricle and thalamus). Head circumference would also be measured in this plane. (b) Normal choroid plexuses (C) and midline falx and interhemispheric fissure (arrows). Note that choroid plexuses extend from the medial to the lateral border of the posterior horn. Lateral walls of anterior horns are indicated by arrowheads.

growth later in pregnancy, appropriate obstetric care in general and management of preterm or post-term pregnancies in particular^{44,45}. Except in pregnancies arising following assisted reproductive technology, the exact day of conception cannot be determined reliably and, therefore, dating a pregnancy by ultrasound appears to be the most reliable method with which to establish true gestational age^{39,46}. It has been recommended, therefore, that all pregnant women be offered an early ultrasound scan between 10 and 13 completed weeks (10+0 to 13+6 weeks) to determine gestational age and to detect multiple pregnancies⁴⁷. In the first trimester, many parameters are related closely to gestational age, but CRL appears to be the most precise, allowing accurate determination of the

day of conception, to within 5 days either way in 95% of cases^{48–52}.

At very early gestations, when the fetus is relatively small, measurement errors will have a more significant effect on gestational age assessment; the optimal time for assessment appears, therefore, to be somewhere between 8 and 13+6 weeks⁴⁸. **(GOOD PRACTICE POINT)**

At 11 to 13+6 weeks, the CRL and BPD are the two most commonly measured parameters for pregnancy dating. Many authors have published nomograms for these variables. Measurements can be made transabdominally or transvaginally. Singleton nomograms remain valid and can be applied in the case of multiple pregnancy^{27,53}. Details of a few published nomograms are provided in Table 1. It is recommended that CRL measurement should be used to determine gestational age unless it is above 84 mm; after this stage, HC can be used, as it becomes slightly more precise than is BPD⁴¹. **(GOOD PRACTICE POINT)**

5. Assessment of fetal anatomy

The second-trimester '18–22-week' scan remains the standard of care for fetal anatomical evaluation in both low-risk and high-risk pregnancies^{54–57}. First-trimester evaluation of fetal anatomy and detection of anomalies was introduced in the late 1980s and early 1990s with the advent of effective transvaginal probes^{58,59}. The introduction of NT aneuploidy screening in the 11 to 13+6-week window has rekindled an interest in early anatomy scanning (Table 2). Reported advantages include early detection and exclusion of many major anomalies, early reassurance to at-risk mothers, earlier genetic diagnosis and easier pregnancy termination if appropriate. Limitations include need for trained and experienced personnel, uncertain cost/benefit ratio and late development of some anatomical structures and pathologies (e.g. corpus callosum, hypoplastic left heart), which make early detection impossible and can lead to difficulties in counseling due to the uncertain clinical significance of some findings^{54–56,60–62}.

Head

Cranial bone ossification should be visible by 11 completed weeks (Figure 2a). It is helpful to look specifically for bone ossification in the axial and coronal planes. No bony defects (distortion or disruption) of the skull should be present.

The cerebral region at 11 to 13+6 weeks is dominated by lateral ventricles that appear large and are filled with the echogenic choroid plexuses in their posterior two thirds (Figure 2b). The hemispheres should appear symmetrical and separated by a clearly visible interhemispheric fissure and falx. The brain mantle is very thin and best appreciated anteriorly, lining the large fluid-filled ventricles, an appearance which should not be mistaken for hydrocephalus. At this early age, some cerebral structures (e.g. corpus

Table 1 Biometry nomograms for consideration in first trimester to around 13 + 6 weeks

Reference	Structure measured	Age range (weeks)	Notes
Robinson & Fleming ⁵² (1975); quoted by Loughna <i>et al.</i> ⁴¹ (2009)	CRL	9 to 13 + 6	Selected for use by British Medical Ultrasound Society ⁴¹
Hadlock <i>et al.</i> ⁸³ (1992)	CRL	5.0 to 18.0	
Daya ⁸⁴ (1993)	CRL	6.1 to 13.3	
Verburg <i>et al.</i> ⁴³ (2008)	CRL	6 + 2 to 15 + 0	Includes BPD, HC, AC, femur, cerebellum
McLennan & Schluter ⁸⁵ (2008)	CRL	5 to 14	Includes BPD to 14 weeks
Hadlock <i>et al.</i> ⁸⁶ (1982)	BPD	12 to 40	In early pregnancy 1982 chart more accurate than 1984 chart
Altman & Chitty ³⁹ (1997); quoted by Loughna <i>et al.</i> ⁴¹ (2009)	BPD	12 + 6 to 35 + 4	Selected for use by British Medical Ultrasound Society ⁴¹
Verburg <i>et al.</i> ⁴³ (2008)	BPD	10 to 43	Includes CRL, HC, AC, femur, cerebellum

Measurements should be performed according to techniques described in these articles and tested on the local population before being adopted into practice. BPD, biparietal diameter; CRL, crown–rump length.

Table 2 Suggested anatomical assessment at time of 11 to 13 + 6-week scan

Organ/anatomical area	Present and/or normal?
Head	Present Cranial bones Midline falx Choroid-plexus-filled ventricles
Neck	Normal appearance Nuchal translucency thickness (if accepted after informed consent and trained/certified operator available)*
Face	Eyes with lens* Nasal bone* Normal profile/mandible* Intact lips*
Spine	Vertebrae (longitudinal and axial)* Intact overlying skin*
Chest	Symmetrical lung fields No effusions or masses
Heart	Cardiac regular activity Four symmetrical chambers*
Abdomen	Stomach present in left upper quadrant Bladder* Kidneys*
Abdominal wall	Normal cord insertion No umbilical defects
Extremities	Four limbs each with three segments Hands and feet with normal orientation*
Placenta	Size and texture
Cord	Three-vessel cord*

*Optional structures. Modified from Fong *et al.*²⁸, McAuliffe *et al.*⁸⁷, Taipale *et al.*⁶⁰ and von Kaisenberg *et al.*⁸⁸.

callosum, cerebellum) are not sufficiently developed to allow accurate assessment. It has been proposed that the posterior fossa intracranial translucency can be evaluated between 11 and 13 + 6 weeks as a screening test for open neural tube defect, but this is not a standard⁶³. At 11 to 13 + 6 weeks, an attempt can be made to visualize the eyes with their lenses, interorbital distances, the profile including the nose, the nasal bone and mandible as well as the integrity of the mouth and lips^{28,64,65} (Figure 3).

However, in absence of obvious anomaly, failure to examine the fetal face at this time should not prompt further examination earlier than the mid-trimester scan.

Neck

Sonographic assessment of NT is part of the screening for chromosomal anomalies and is discussed below. Attention should be paid to proper alignment of the neck with the trunk and identification of other fluid collections such as hygromas and jugular lymph sacs^{28,65}.

Spine

Longitudinal and axial views should be obtained to show normal vertebral alignment and integrity, and an attempt should be made to show intact overlying skin (Figure 4). However, in the absence of obvious anomaly, failure to examine the spine at this time should not prompt further examination earlier than the mid-trimester scan. Particular attention should be paid to the normal appearance of the spine when BPD < 5th centile⁶⁶.

Thorax

The chest normally contains lungs of homogeneous echogenicity on ultrasound, without evidence of pleural effusions or cystic or solid masses. Diaphragmatic continuity should be evaluated, noting normal intra-abdominal position of stomach and liver.

Heart

The normal position of the heart on the left side of the chest (levocardia) should be documented (Figure 5). More detailed sonographic assessment of cardiac anatomy has been demonstrated to be feasible at 11 to 13 + 6 weeks^{67,68}, but this is not part of routine assessment. For safety reasons, use of Doppler is not indicated during routine scanning.

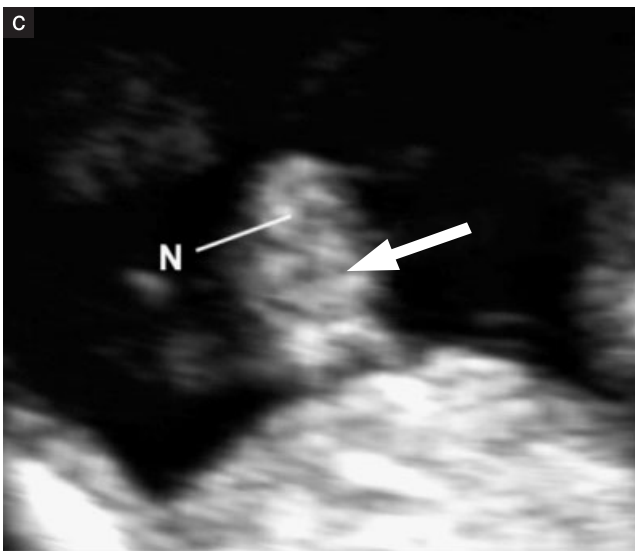
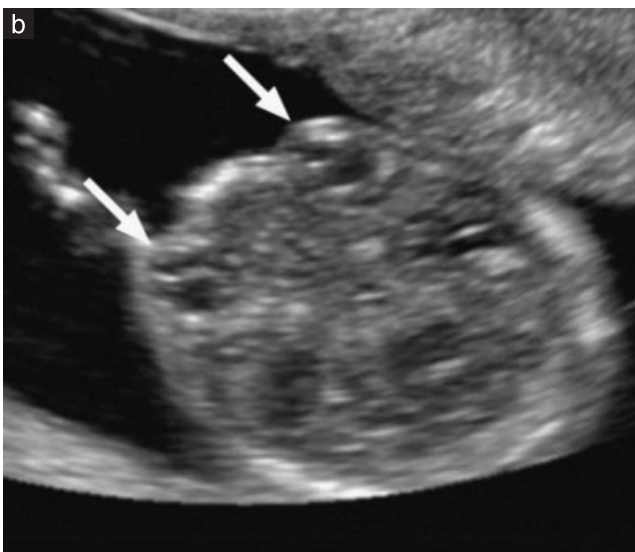
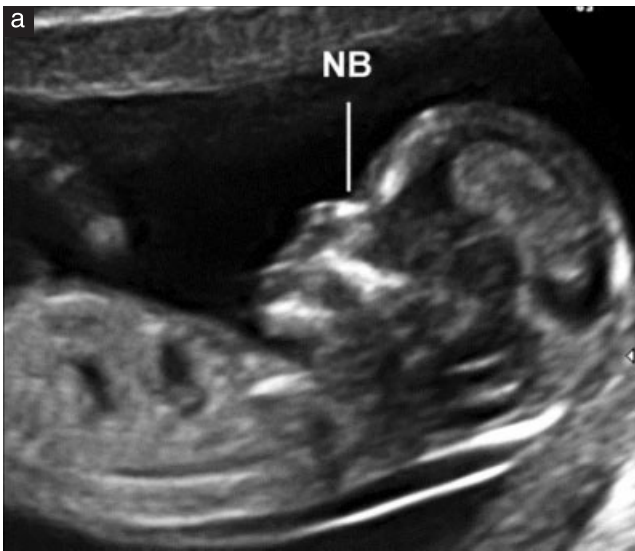


Figure 3 Fetal face. (a) Normal profile showing nasal bones (NB). Note normal length of maxilla and mandible. (b) Normal eyes with globes and lenses (arrows) visible. (c) Fetal lips at 13 weeks. Note intact upper lip and line between the lips (arrow). Nasal detail (N) is limited.

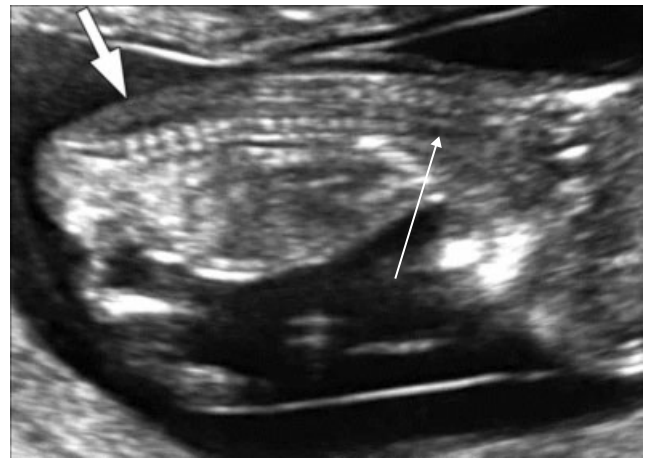


Figure 4 Fetal spine. Intact skin (short thick arrow) is visible posterior to the vertebrae from neck to sacrum in a true median view. Note vertebral bodies show ossification, but neural arches, which are still cartilaginous, are isoechoic or hypoechoic. In cervical region (long arrow) the vertebral bodies have not yet ossified and the cartilaginous anlage is hypoechoic; this is normal.

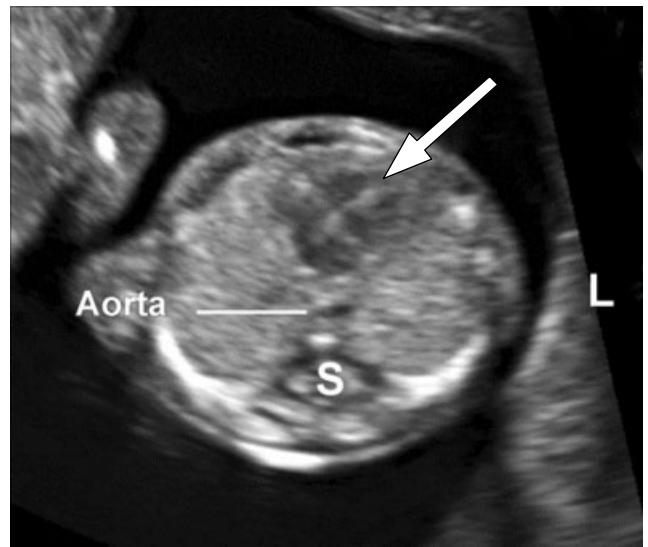


Figure 5 Axial section of the fetal thorax at the level of the four-chamber view of the heart, with the cardiac apex pointing to the left (L). Note atria and ventricles are symmetrical on either side of the septum (arrow). Lung fields are of homogeneous echogenicity and symmetrical. Aorta is just to left side of spine (S).

Abdominal content

At 11 to 13 + 6 weeks, the stomach and bladder are the only hypoechoic fluid structures in the abdomen (Figure 6a and 6b). The position of the stomach on the left side of the abdomen together with levocardia helps confirm normal situs visceralis. The fetal kidneys should be noted in their expected paraspinous location as bean-shaped slightly echogenic structures with typical hypoechoic central renal pelvis (Figure 6b). By 12 weeks of gestation, the fetal bladder should be visible as a median hypoechoic round structure in the lower abdomen.

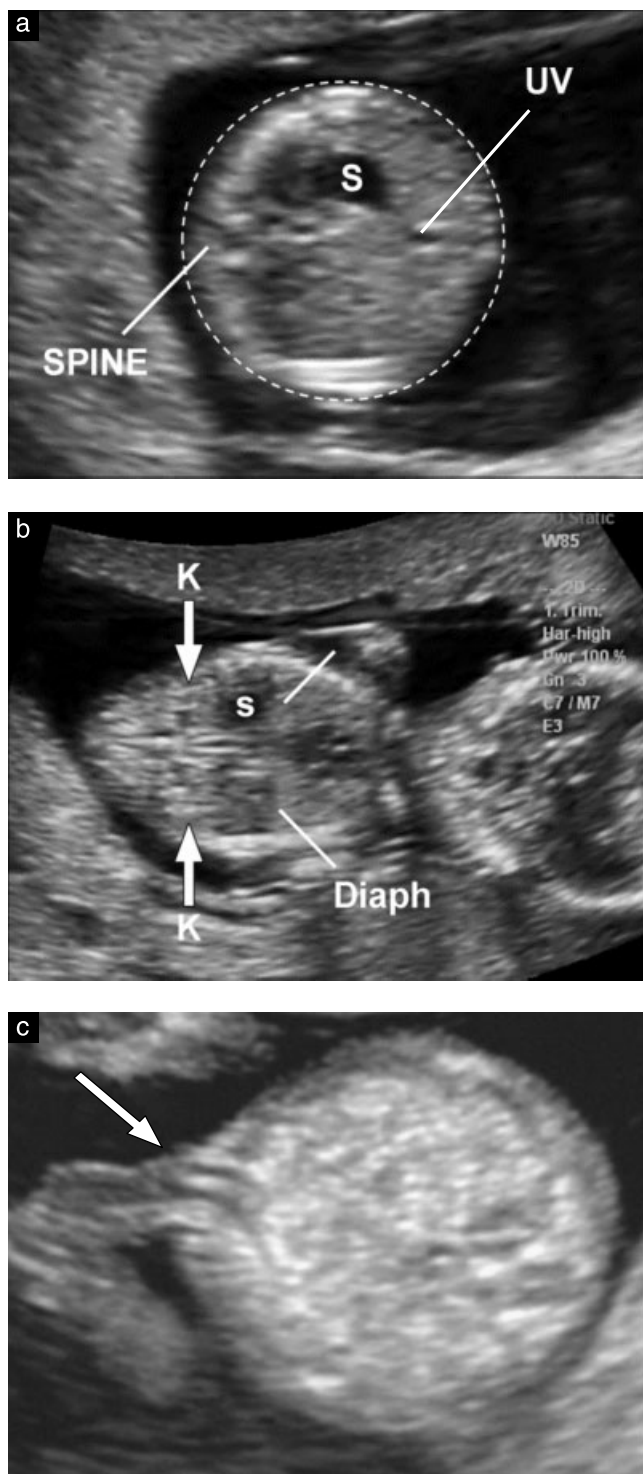


Figure 6 Fetal abdomen. (a) Axial view of abdomen at level at which abdominal circumference is measured (dashed line), showing stomach (S) and umbilical vein (UV). (b) Coronal view of abdomen showing kidneys with central hypoechoic renal pelvis (K, arrows), stomach (S) and diaphragm (Diaph, lines). (c) Umbilical cord insertion (arrow). Note that the two umbilical arteries are visible.

Abdominal wall

The normal insertion of the umbilical cord should be documented after 12 weeks (Figure 6c). The physiological umbilical hernia is present up to 11 weeks

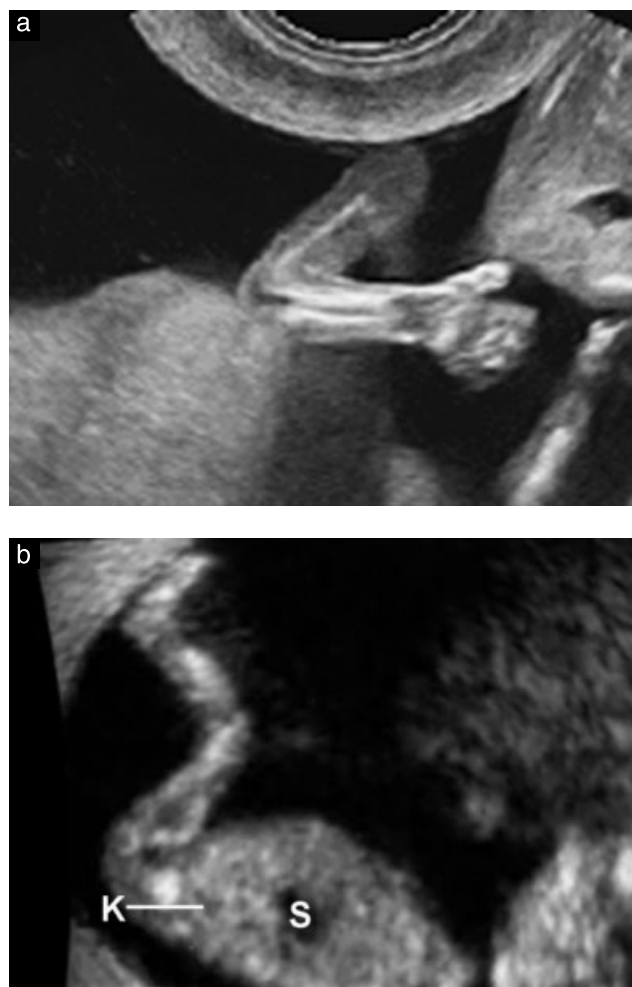


Figure 7 Fetal limbs. (a) Normal arm showing normal alignment of hand and wrist. (b) Normal leg showing normal orientation of foot with respect to lower leg. Also visible are kidney (K) and stomach (S).

and should be differentiated from omphalocele and gastroschisis^{28,65,69}.

Limbs

The presence of each bony segment of the upper and lower limbs and presence and normal orientation of the two hands and feet should be noted at the 11 to 13 + 6-week ultrasound scan. The terminal phalanges of the hands may be visible at 11 weeks, especially with transvaginal scanning (Figure 7a).

Genitalia

The evaluation of genitalia and gender is based upon the orientation of the genital tubercle in the mid-sagittal plane, but is not sufficiently accurate to be used for clinical purposes.

Umbilical cord

The number of cord vessels, cord insertion at the umbilicus and presence of cord cysts should be noted. Brief evaluation of the paravesical region with color or

power Doppler can be helpful in confirming the presence of two umbilical arteries, but this is not part of the routine assessment.

Role of three-dimensional (3D) and 4D ultrasound

Three-dimensional (3D) and 4D ultrasound are not currently used for routine first-trimester fetal anatomical evaluation, as their resolution is not yet as good as that of 2D ultrasound. In expert hands, these methods may be helpful in evaluation of abnormalities, especially those of surface anatomy⁷⁰.

6. Chromosomal anomaly assessment

Ultrasound-based screening for chromosomal anomalies in the first trimester may be offered, depending on public health policies, trained personnel and availability of healthcare resources. The first-trimester screening should include NT measurement^{71,72}. Screening performance is further improved by the addition of other markers, including biochemical measurement of free beta or total human chorionic gonadotropin (hCG) and pregnancy-associated plasma protein-A (PAPP-A)⁷³. In appropriate circumstances, additional aneuploidy markers, including nasal bone, tricuspid regurgitation, ductal regurgitation and others, may be sought by personnel with appropriate training and certification^{74–76}. Most experts recommend that NT should be measured between 11 and 13 + 6 weeks, corresponding to a CRL measurement of between 45 and 84 mm. This gestational age window is chosen because NT as a screening test performs optimally and fetal size allows diagnosis of major fetal abnormalities, thus providing women who are carrying an affected fetus with the option of an early termination of pregnancy⁷⁷. NT implementation requires several elements to be in place, including suitable equipment, counseling and management as well as operators with specialized training and continuing certification. Further details can be obtained from relevant national bodies and charities such as The Fetal Medicine Foundation (www.fetalmedicine.com). However, even in the absence of NT-based screening programs, qualitative evaluation of the nuchal region of any fetus is recommended and, if it appears thickened, expert referral should be considered.

How to measure NT

NT measurements used for screening should only be done by trained and certified operators. NT can be measured by a transabdominal or transvaginal route. The fetus should be in a neutral position, a sagittal section should be obtained and the image should be magnified in order to include only the fetal head and upper thorax. Furthermore, the amniotic membrane should be identified separately from the fetus. The median view of the fetal face is defined by the presence of the echogenic tip of

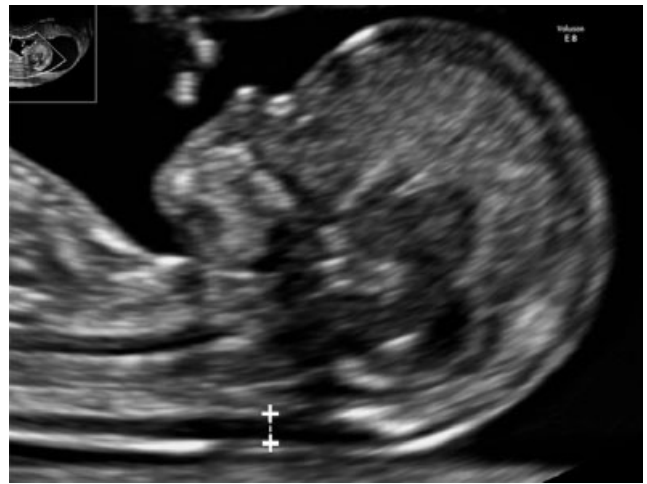

Figure 8 Sonographic measurement of nuchal translucency thickness.

the nose and rectangular shape of the palate anteriorly, the translucent diencephalon in the center and the nuchal membrane posteriorly. If the section is not exactly median, the tip of the nose will not be visualized and the orthogonal osseous extension at the frontal end of the maxilla will appear. The ultrasound machine should allow measurement precision of 0.1 mm. Calipers should be placed correctly (on-on) to measure NT as the maximum distance between the nuchal membrane and the edge of the soft tissue overlying the cervical spine (Figure 8). If more than one measurement meeting all the criteria is obtained, the maximum one should be recorded and used for risk assessment. Multiple pregnancy requires special considerations, taking into account chorionicity.

How to train and control for the quality of NT measurement

A reliable and reproducible measurement of NT requires appropriate training. A rigorous audit of operator performance and constructive feedback from assessors has been established in many countries and should be considered essential for all practitioners who participate in NT-based screening programs. **(GOOD PRACTICE POINT)**

7. Other intra- and extrauterine structures

The echostructure of the placenta should be evaluated. Clearly abnormal findings, such as masses, single or multiple cystic spaces or large subchorionic fluid collection (> 5 cm), should be noted and followed up. Position of the placenta in relation to the cervix is of less importance at this stage of pregnancy since most 'migrate' away from the internal cervical os⁷⁸. Placenta previa should not be reported at this stage.

Special attention should be given to patients with a prior Cesarean section, who may be predisposed to scar pregnancy or placenta accreta, with significant complications. In these patients, the area between the bladder and

the uterine isthmus at the site of the Cesarean section scar should be scrutinized. In suspected cases, consideration should be given to prompt specialist referral for further evaluation and management^{79,80}. Although the issue of routine scans in women with a history of Cesarean section may be raised in the future^{81,82}, there is currently insufficient evidence to support inclusion of such a policy in routine practice.

Gynecological pathology, both benign and malignant, may be detected during any first-trimester scan. Abnormalities of uterine shape, such as uterine septa and bicornuate uteri, should be described. The adnexa should be surveyed for abnormalities and masses. The relevance and management of such findings are beyond the scope of these Guidelines.

GUIDELINE AUTHORS

L. J. Salomon*, Department of Obstetrics and Fetal Medicine and SFAPE (Société Française d'Amélioration des Pratiques Echographique), Paris Descartes University, Assistance Publique-Hopitaux de Paris, Hopital Necker Enfants, Paris, France

Z. Alfirevic*, Department for Women's and Children's Health, University of Liverpool, Liverpool, UK

C. M. Bilardo, Fetal Medicine Unit, Department of Obstetrics and Gynaecology, University Medical Centre Groningen, Groningen, The Netherlands

G. E. Chalouhi, Department of Obstetrics and Fetal Medicine and SFAPE (Société Française d'Amélioration des Pratiques Echographique), Paris Descartes University, Assistance Publique-Hopitaux de Paris, Hopital Necker Enfants, Paris, France

T. Ghi, Department of Obstetrics and Gynaecology, Policlinico S.Orsola-Malpighi, University of Bologna, Bologna, Italy

K. O. Kagan, Department of Obstetrics and Gynecology, University of Tuebingen, Tuebingen, Germany

T. K. Lau, Fetal Medicine Centre, Paramount Clinic, Central, Hong Kong

A. T. Papageorghiou, Fetal Medicine Unit, St George's, University of London, London, UK

N. J. Raine-Fenning, Division of Obstetrics & Gynaecology, School of Clinical Sciences, University of Nottingham, Nottingham, UK

J. Stirnemann, Obstetrics and Fetal Medicine, GHU Necker-Enfants Malades, University Paris Descartes, Paris, France

S. Suresh, Mediscan Systems & Fetal Care Research Foundation, Mylapore, Chennai, India

A. Tabor, Fetal Medicine Unit, Department of Obstetrics, Rigshospitalet, Copenhagen University Hospital, Copenhagen, Denmark

I. E. Timor-Tritsch, Department of Obstetrics and Gynecology, New York University School of Medicine, New York, NY, USA

A. Toi, Medical Imaging and Obstetrics and Gynaecology, Mount Sinai Hospital, University of Toronto, Toronto, ON, Canada

G. Yeo, Department of Maternal Fetal Medicine, Obstetric Ultrasound and Prenatal Diagnostic Unit, KK Women's and Children's Hospital, Singapore

*L. J. S. and Z. A. contributed equally to this article.

CITATION

These Guidelines should be cited as: 'Salomon LJ, Alfirevic Z, Bilardo CM, Chalouhi GE, Ghi T, Kagan KO, Lau TK, Papageorghiou AT, Raine-Fenning NJ, Stirnemann J, Suresh S, Tabor A, Timor-Tritsch IE, Toi A, Yeo G. ISUOG Practice Guidelines: performance of first-trimester fetal ultrasound scan. *Ultrasound Obstet Gynecol* 2013; **41**: 102–113.'

REFERENCES

- Salomon LJ, Alfirevic Z, Berghella V, Bilardo C, Hernandez-Andrade E, Johnsen SL, Kalache K, Leung KY, Malinge G, Munoz H, Prefumo F, Toi A, Lee W; ISUOG Clinical Standards Committee. Practice guidelines for performance of the routine mid-trimester fetal ultrasound scan. *Ultrasound Obstet Gynecol* 2011; **37**: 116–126.
- Deter RL, Buster JE, Casson PR, Carson SA. Individual growth patterns in the first trimester: evidence for difference in embryonic and fetal growth rates. *Ultrasound Obstet Gynecol* 1999; **13**: 90–98.
- Blaas HG. The examination of the embryo and early fetus: how and by whom? *Ultrasound Obstet Gynecol* 1999; **14**: 153–158.
- Whitworth M, Bricker L, Neilson JP, Dowswell T. Ultrasound for fetal assessment in early pregnancy. *Cochrane Database Syst Rev* 2010; **4**: CD007058.
- Bennett KA, Crane JMG, O'Shea P, Lacelle J, Hutchens D, Copel JA. First trimester ultrasound screening is effective in reducing postterm labor induction rates: a randomized controlled trial. *Am J Obstet Gynecol* 2004; **190**: 1077–1081.
- Hoffman CS, Messer LC, Mendola P, Savitz DA, Herring AH, Hartmann KE. Comparison of gestational age at birth based on last menstrual period and ultrasound during the first trimester. *Paediatr Perinat Epidemiol* 2008; **22**: 587–596.
- Taipale P, Hiilesmaa V. Predicting delivery date by ultrasound and last menstrual period in early gestation. *Obstet Gynecol* 2001; **97**: 189–194.
- Skalkidou A, Kieler H, Stephansson O, Roos N, Cnattingius S, Haglund B. Ultrasound pregnancy dating leads to biased perinatal morbidity and neonatal mortality among post-term-born girls. *Epidemiology* 2010; **21**: 791–796.
- Harrington DJ, MacKenzie IZ, Thompson K, Fleminger M, Greenwood C. Does a first trimester dating scan using crown rump length measurement reduce the rate of induction of labour for prolonged pregnancy? An uncompleted randomised controlled trial of 463 women. *BJOG* 2006; **113**: 171–176.
- Ott WJ. Accurate gestational dating: revisited. *Am J Perinatol* 1994; **11**: 404–408.
- Wisser J, Dirschedl P, Krone S. Estimation of gestational age by transvaginal sonographic measurement of greatest embryonic length in dated human embryos. *Ultrasound Obstet Gynecol* 1994; **4**: 457–462.
- Tunón K, Eik-Nes SH, Grøttum P, Von Düring V, Kahn JA. Gestational age in pregnancies conceived after *in vitro* fertilization: a comparison between age assessed from oocyte retrieval, crown-rump length and biparietal diameter. *Ultrasound Obstet Gynecol* 2000; **15**: 41–46.
- Grange G, Pannier E, Goffinet F, Cabrol D, Zorn JR. Dating biometry during the first trimester: accuracy of an every-day practice. *Eur J Obstet Gynecol Reprod Biol* 2000; **88**: 61–64.


14. Chalouhi GE, Bernard JP, Benoist G, Nasr B, Ville Y, Salomon LJ. A comparison of first trimester measurements for prediction of delivery date. *J Matern Fetal Neonatal Med* 2011; **24**: 51–57.
15. Salomon LJ, Pizzi C, Gasparrini A, Bernard J-P, Ville Y. Prediction of the date of delivery based on first trimester ultrasound measurements: an independent method from estimated date of conception. *J Matern Fetal Neonatal Med* 2010; **23**: 1–9.
16. Caughey AB, Nicholson JM, Washington AE. First- vs second-trimester ultrasound: the effect on pregnancy dating and perinatal outcomes. *Am J Obstet Gynecol* 2008; **198**: 703.e1–6.
17. Thorsell M, Kaijser M, Almström H, Andolf E. Expected day of delivery from ultrasound dating versus last menstrual period-obstetric outcome when dates mismatch. *BJOG* 2008; **115**: 585–589.
18. Bottomley C, Bourne T. Dating and growth in the first trimester. *Best Pract Res Clin Obstet Gynaecol* 2009; **4**: 439–452.
19. Sonek J. First trimester ultrasonography in screening and detection of fetal anomalies. *Am J Med Genet C Semin Med Genet* 2007; **145**: 45–61.
20. Snijders RJ, Johnson S, Sebire NJ, Noble PL, Nicolaides KH. First-trimester ultrasound screening for chromosomal defects. *Ultrasound Obstet Gynecol* 1996; **7**: 216–226.
21. Ville Y. ‘Ceci n’est pas une échographie’: a plea for quality assessment in prenatal ultrasound. *Ultrasound Obstet Gynecol* 2008; **31**: 1–5.
22. Abramowicz JS, Kossoff G, Marsal K, Ter Haar G. Safety Statement, 2000 (reconfirmed 2003). International Society of Ultrasound in Obstetrics and Gynecology (ISUOG). *Ultrasound Obstet Gynecol* 2003; **21**: 100.
23. Torloni MR, Vedmedovska N, Merialdi M, Betrán AP, Allen T, González R, Platt LD; ISUOG-WHO Fetal Growth Study Group. Safety of ultrasonography in pregnancy: WHO systematic review of the literature and meta-analysis. *Ultrasound Obstet Gynecol* 2009; **33**: 599–608.
24. Hershkovitz R, Sheiner E, Mazor M. Ultrasound in obstetrics: a review of safety. *Eur J Obstet Gynecol Reprod Biol* 2002; **101**: 15–18.
25. Salvesen K, Lees C, Abramowicz J, Brezinka C, Ter Haar G, Maršál K. ISUOG statement on the safe use of Doppler in the 11 to 13 + 6-week fetal ultrasound examination. *Ultrasound Obstet Gynecol* 2011; **37**: 628.
26. Lewi L, Jani J, Blickstein I, Huber A, Gucciardo L, Van Mieghem T, Doné E, Boes AS, Hecher K, Gratacós E, Lewi P, Deprest J. The outcome of mono chorionic diamniotic twin gestations in the era of invasive fetal therapy: a prospective cohort study. *Am J Obstet Gynecol* 2008; **199**: 493.e1–7.
27. Dias T, Arcangeli T, Bhide A, Napolitano R, Mahsud-Dornan S, Thilaganathan B. First-trimester ultrasound determination of chorionicity in twin pregnancy. *Ultrasound Obstet Gynecol* 2011; **38**: 530–532.
28. Fong KW, Toi A, Salem S, Hornberger LK, Chitayat D, Keating SJ, McAuliffe F, Johnson JA. Detection of fetal structural abnormalities with US during early pregnancy. *Radiographics* 2004; **24**: 157–174.
29. Jurkovic D, Gruboeck K, Campbell S. Ultrasound features of normal early pregnancy development. *Curr Opin Obstet Gynecol* 1995; **7**: 493–504.
30. Tezuka N, Sato S, Kanasugi H, Hiroi M. Embryonic heart rates: development in early first trimester and clinical evaluation. *Gynecol Obstet Invest* 1991; **32**: 210–212.
31. Levi CS, Lyons EA, Zheng XH, Lindsay DJ, Holt SC. Endovaginal US: demonstration of cardiac activity in embryos of less than 5.0 mm in crown-rump length. *Radiology* 1990; **176**: 71–74.
32. Goldstein SR. Significance of cardiac activity on endovaginal ultrasound in very early embryos. *Obstet Gynecol* 1992; **80**: 670–672.
33. Brown DL, Emerson DS, Felker RE, Cartier MS, Smith WC. Diagnosis of early embryonic demise by endovaginal sonography. *J Ultrasound Med* 1990; **9**: 631–636.
34. Oh JS, Wright G, Coulam CB. Gestational sac diameter in very early pregnancy as a predictor of fetal outcome. *Ultrasound Obstet Gynecol* 2002; **20**: 267–269.
35. Robinson HP, Sweet EM, Adam AH. The accuracy of radiological estimates of gestational age using early fetal crown-rump length measurements by ultrasound as a basis for comparison. *Br J Obstet Gynaecol* 1979; **86**: 525–528.
36. Robinson HP. “Gestation sac” volumes as determined by sonar in the first trimester of pregnancy. *Br J Obstet Gynaecol* 1975; **82**: 100–107.
37. Salomon LJ, Bernard M, Amarsy R, Bernard JP, Ville Y. The impact of crown-rump length measurement error on combined Down syndrome screening: a simulation study. *Ultrasound Obstet Gynecol* 2009; **33**: 506–511.
38. Sladkevicius P, Saltvedt S, Almström H, Kublickas M, Grunewald C, Valentin L. Ultrasound dating at 12–14 weeks of gestation. A prospective cross-validation of established dating formulae in *in-vitro* fertilized pregnancies. *Ultrasound Obstet Gynecol* 2005; **26**: 504–511.
39. Altman DG, Chitty LS. New charts for ultrasound dating of pregnancy. *Ultrasound Obstet Gynecol* 1997; **10**: 174–191.
40. Salomon LJ, Bernard JP, Duyme M, Dorion A, Ville Y. Revisiting first-trimester fetal biometry. *Ultrasound Obstet Gynecol* 2003; **22**: 63–66.
41. Loughna P, Chitty L, Evans T, Chudleigh T. Fetal size and dating: charts recommended for clinical obstetric practice. *Ultrasound* 2009; **17**: 161–167.
42. Hadlock FP, Deter RL, Carpenter RJ, Park SK. Estimating fetal age: effect of head shape on BPD. *AJR Am J Roentgenol* 1981; **137**: 83–85.
43. Verburg BO, Steegers EAP, De Ridder M, Snijders RJM, Smith E, Hofman A, Moll HA, Jaddoe VW, Witteman JC. New charts for ultrasound dating of pregnancy and assessment of fetal growth: longitudinal data from a population-based cohort study. *Ultrasound Obstet Gynecol* 2008; **31**: 388–396.
44. Crowley P. Interventions for preventing or improving the outcome of delivery at or beyond term. *Cochrane Database Syst Rev* 2000; (2): CD000170.
45. Mongelli M, Wong YC, Venkat A, Chua TM. Induction policy and missed post-term pregnancies: a mathematical model. *Aust N Z J Obstet Gynaecol* 2001; **41**: 38–40.
46. Hoffman CS, Messer LC, Mendola P, Savitz DA, Herring AH, Hartmann KE. Comparison of gestational age at birth based on last menstrual period and ultrasound during the first trimester. *Paediatr Perinat Epidemiol* 2008; **22**: 587–596.
47. NICE. Antenatal care: Routine care for the healthy pregnant woman. National Institute for Health and Clinical Excellence: London, 2010.
48. Savitz DA, Terry JW, Dole N, Thorp JM, Siega-Riz AM, Herring AH. Comparison of pregnancy dating by last menstrual period, ultrasound scanning, and their combination. *Am J Obstet Gynecol* 2002; **187**: 1660–1666.
49. Bagratee JS, Regan L, Khullar V, Connolly C, Moodley J. Reference intervals of gestational sac, yolk sac and embryo volumes using three-dimensional ultrasound. *Ultrasound Obstet Gynecol* 2009; **34**: 503–509.
50. Grisolia G, Milano K, Pilu G, Banzi C, David C, Gabrielli S, Rizzo N, Morandi R, Bovicelli L. Biometry of early pregnancy with transvaginal sonography. *Ultrasound Obstet Gynecol* 1993; **3**: 403–411.
51. Robinson HP. Sonar measurement of fetal crown-rump length as means of assessing maturity in first trimester of pregnancy. *Br Med J* 1973; **4**: 28–31.
52. Robinson HP, Fleming JE. A critical evaluation of sonar “crown-rump length” measurements. *Br J Obstet Gynaecol* 1975; **82**: 702–710.
53. Dias T, Mahsud-Dornan S, Thilaganathan B, Papageorghiou A, Bhide A. First-trimester ultrasound dating of twin pregnancy: are singleton charts reliable? *BJOG* 2010; **117**: 979–984.
54. Saltvedt S, Almström H, Kublickas M, Valentin L, Grunewald C. Detection of malformations in chromosomally normal fetuses

- by routine ultrasound at 12 or 18 weeks of gestation—a randomised controlled trial in 39,572 pregnancies. *BJOG* 2006; **113**: 664–674.
55. Chen M, Lee CP, Lam YH, Tang RYK, Chan BCP, Wong SF, Tse LH, Tang MH. Comparison of nuchal and detailed morphology ultrasound examinations in early pregnancy for fetal structural abnormality screening: a randomized controlled trial. *Ultrasound Obstet Gynecol* 2008; **31**: 136–146; discussion 146.
 56. Timor-Tritsch IE, Fuchs KM, Monteagudo A, D'Alton ME. Performing a fetal anatomy scan at the time of first-trimester screening. *Obstet Gynecol* 2009; **113**: 402–407.
 57. Abu-Rustum RS, Daou L, Abu-Rustum SE. Role of first-trimester sonography in the diagnosis of aneuploidy and structural fetal anomalies. *J Ultrasound Med* 2010; **29**: 1445–1452.
 58. Timor-Tritsch IE, Bashiri A, Monteagudo A, Arslan AA. Qualified and trained sonographers in the US can perform early fetal anatomy scans between 11 and 14 weeks. *Am J Obstet Gynecol* 2004; **191**: 1247–1252.
 59. Bronshtein M, Zimmer EZ. Transvaginal ultrasound diagnosis of fetal clubfeet at 13 weeks, menstrual age. *J Clin Ultrasound*. 1989; **17**: 518–520.
 60. Taipale P, Ammälä M, Salonen R, Hiilesmaa V. Learning curve in ultrasonographic screening for selected fetal structural anomalies in early pregnancy. *Obstet Gynecol* 2003; **101**: 273–278.
 61. Cedergren M, Selbing A. Detection of fetal structural abnormalities by an 11–14-week ultrasound dating scan in an unselected Swedish population. *Acta Obstet Gynecol Scand* 2006; **85**: 912–915.
 62. Fisher J. First-trimester screening: dealing with the fall-out. *Prenat Diagn* 2011; **31**: 46–49.
 63. Chaoui R, Nicolaides KH. From nuchal translucency to intracranial translucency: towards the early detection of spina bifida. *Ultrasound Obstet Gynecol* 2010; **35**: 133–138.
 64. Sepulveda W, Wong AE, Martinez-Ten P, Perez-Pedregosa J. Retronasal triangle: a sonographic landmark for the screening of cleft palate in the first trimester. *Ultrasound Obstet Gynecol* 2010; **35**: 7–13.
 65. Syngelaki A, Chelemen T, Dagklis T, Allan L, Nicolaides KH. Challenges in the diagnosis of fetal non-chromosomal abnormalities at 11–13 weeks. *Prenat Diagn* 2011; **31**: 90–102.
 66. Bernard J-P, Cuckle HS, Stirnemann JJ, Salomon LJ, Ville Y. Screening for fetal spina bifida by ultrasound examination in the first trimester of pregnancy using fetal biparietal diameter. *Am J Obstet Gynecol* 2012; **207**: 306.e1–5.
 67. DeVore GR. First-trimester fetal echocardiography: is the future now? *Ultrasound Obstet Gynecol* 2002; **20**: 6–8.
 68. Yagel S, Cohen SM, Messing B. First and early second trimester fetal heart screening. *Curr Opin Obstet Gynecol* 2007; **19**: 183–190.
 69. van Zalen-Sprock RM, Vugt JM, van Geijn HP. First-trimester sonography of physiological midgut herniation and early diagnosis of omphalocele. *Prenat Diagn* 1997; **17**: 511–518.
 70. Bhaduri M, Fong K, Toi A, Tomlinson G, Okun N. Fetal anatomic survey using three-dimensional ultrasound in conjunction with first-trimester nuchal translucency screening. *Prenat Diagn* 2010; **30**: 267–273.
 71. Nicolaides KH, Azar G, Byrne D, Mansur C, Marks K. Fetal nuchal translucency: ultrasound screening for chromosomal defects in first trimester of pregnancy. *BMJ*; 1992; **304**: 867–869.
 72. Nicolaides KH, Snijders RJ, Gosden CM, Berry C, Campbell S. Ultrasonographically detectable markers of fetal chromosomal abnormalities. *Lancet* 1992; **340**: 704–707.
 73. Kagan KO, Wright D, Baker A, Sahota D, Nicolaides KH. Screening for trisomy 21 by maternal age, fetal nuchal translucency thickness, free beta-human chorionic gonadotropin and pregnancy-associated plasma protein-A. *Ultrasound Obstet Gynecol* 2008; **31**: 618–624.
 74. Kagan KO, Cicero S, Staboulidou I, Wright D, Nicolaides KH. Fetal nasal bone in screening for trisomies 21, 18 and 13 and Turner syndrome at 11–13 weeks of gestation. *Ultrasound Obstet Gynecol* 2009; **33**: 259–264.
 75. Kagan KO, Valencia C, Livanos P, Wright D, Nicolaides KH. Tricuspid regurgitation in screening for trisomies 21, 18 and 13 and Turner syndrome at 11+0 to 13+6 weeks of gestation. *Ultrasound Obstet Gynecol* 2009; **33**: 18–22.
 76. Maiz N, Valencia C, Kagan KO, Wright D, Nicolaides KH. Ductus venosus Doppler in screening for trisomies 21, 18 and 13 and Turner syndrome at 11–13 weeks of gestation. *Ultrasound Obstet Gynecol* 2009; **33**: 512–517.
 77. Nicolaides KH. Screening for fetal aneuploidies at 11 to 13 weeks. *Prenat Diagn* 2011; **31**: 7–15.
 78. Mustafá SA, Brizot ML, Carvalho MHB, Watanabe L, Kahhale S, Zugaib M. Transvaginal ultrasonography in predicting placenta previa at delivery: a longitudinal study. *Ultrasound Obstet Gynecol* 2002; **20**: 356–359.
 79. Timor-Tritsch IE, Monteagudo A, Santos R, Tsymbal T, Pineda G, Arslan AA. The diagnosis, treatment, and follow-up of cesarean scar pregnancy. *Am J Obstet Gynecol* 2012; **207**: 44.e1–13.
 80. Timor-Tritsch IE, Monteagudo A. Unforeseen consequences of the increasing rate of cesarean deliveries: early placenta accreta and cesarean scar pregnancy. A review. *Am J Obstet Gynecol* 2012; **207**: 14–29.
 81. Stirnemann JJ, Chalouhi GE, Forner S, Saidji Y, Salomon LJ, Bernard J-P, Ville Y. First-trimester uterine scar assessment by transvaginal ultrasound. *Am J Obstet Gynecol* 2011; **205**: 551.e1–6.
 82. Stirnemann JJ, Mousty E, Chalouhi G, Salomon LJ, Bernard J-P, Ville Y. Screening for placenta accreta at 11–14 weeks of gestation. *Am J Obstet Gynecol* 2011; **205**: 547.e1–6.
 83. Hadlock FP, Shah YP, Kanon DJ, Lindsey JV. Fetal crown-rump length: reevaluation of relation to menstrual age (5–18 weeks) with high-resolution real-time US. *Radiology* 1992; **182**: 501–505.
 84. Daya S. Accuracy of gestational age estimation by means of fetal crown-rump length measurement. *Am J Obstet Gynecol* 1993; **168**: 903–908.
 85. McLennan AC, Schluter PJ. Construction of modern Australian first trimester ultrasound dating and growth charts. *J Med Imaging Radiat Oncol* 2008; **52**: 471–479.
 86. Hadlock FP, Deter RL, Harrist RB, Park SK. Fetal biparietal diameter: a critical re-evaluation of the relation to menstrual age by means of real-time ultrasound. *J Ultrasound Med* 1982; **1**: 97–104.
 87. McAuliffe FM, Fong KW, Toi A, Chitayat D, Keating S, Johnson J-A. Ultrasound detection of fetal anomalies in conjunction with first-trimester nuchal translucency screening: a feasibility study. *Am J Obstet Gynecol* 2005; **193**: 1260–1265.
 88. von Kaisenberg CS, Kuhling-von Kaisenberg H, Fritzer E, Schemm S, Meinhold-Heerlein I, Jonat W. Fetal transabdominal anatomy scanning using standard views at 11 to 14 weeks' gestation. *Am J Obstet Gynecol* 2005; **192**: 535–542.

(Guideline review date: June 2015)

The authorship of this article was incomplete as initially published. This version of the article correctly acknowledges all authors who contributed to the development of the Guidelines.

APPENDIX: ROUTINE ULTRASOUND WORKSHEET (EXAMPLE)



Patient: _____ **ID number:** _____

Date of birth (DD/MM/YYYY): _____
Referring physician: _____

Date of exam (DD/MM/YYYY): _____
Sonographer / Supervisor: _____

Indication for scan and relevant clinical information:

LMP

Technical conditions: *Good / Limited by:*
Singleton / Multiple (use 1 sheet/fetus)
=> Chorionicity:

ADNEXA:
Appearance Normal Abnormal*
Anomaly:

MEASUREMENTS	mm	Centile (Reference range)
Crown-rump length		
Nuchal translucency (optional)		
Biparietal diameter		
Head circumference		
Abdominal circumference		
Femoral diaphysis length		

***Abnormal findings (please detail):**

Ultrasound-based estimate of GA:

.....weeks +days

CONCLUSION:

Normal and complete examination.
 Normal but incomplete examination.
 Abnormal examination*
 Plans: No further ultrasound scans required
 Follow up planned in weeks.
 Referred to
 Other:

SONOGRAPHIC APPEARANCE OF FETAL ANATOMY: (N = Normal; Ab = Abnormal*; NV = Not visualized) Gray = optional	N	Ab*	NV
Head			
Shape			
Cranial ossification			
Midline falx			
Choroid plexus			
Face			
Orbits			
Profile			
Neck			
Thorax			
Pulm. area			
Diaphragm			
Heart			
Heart activity			
Size			
Cardiac axis			
Four-chamber view			
Abdomen			
Stomach			
Bowel			
Kidneys			
Urinary bladder			
Cord insertion / abdominal wall			
Cord vessels			
Spine			
Limbs			
Right arm (incl. hand)			
Right leg (incl. foot)			
Left arm (incl. hand)			
Left leg (incl. foot)			
Gender (optional): <input type="checkbox"/> M <input type="checkbox"/> F			
Other:			

	Produced	Printed	Stored
No. of images			