GYNEKOLOGISEN ULTRAÄÄNITUTKIMUKSEN ALKEET, NORMAALI KOHTU JA MUNASARJAT

Tuula Karipohja, HYKS NaiS

EGO 1.11.2018

SIDONNAISUUDET 2017-2018

- vastuulääkäri, HYKS Naistentaudit ja synnytykset, naistentautien poliklinikka, Ruoholahti
- yksityisvastaanotto: Aava Kamppi
- Valviran asiantuntijalääkäri
- luentopalkkioita: Bayer, UÄ-seura
- asiantuntijalausuntoja: Bayer

High-quality gynecological ultrasound can be highly beneficial,
but poor-quality gynecological ultrasound can do harm.

Lil Valentin

Ultrasound Obstet Gynecol 1999;13:1–7

Aiheena 2D ja TVS

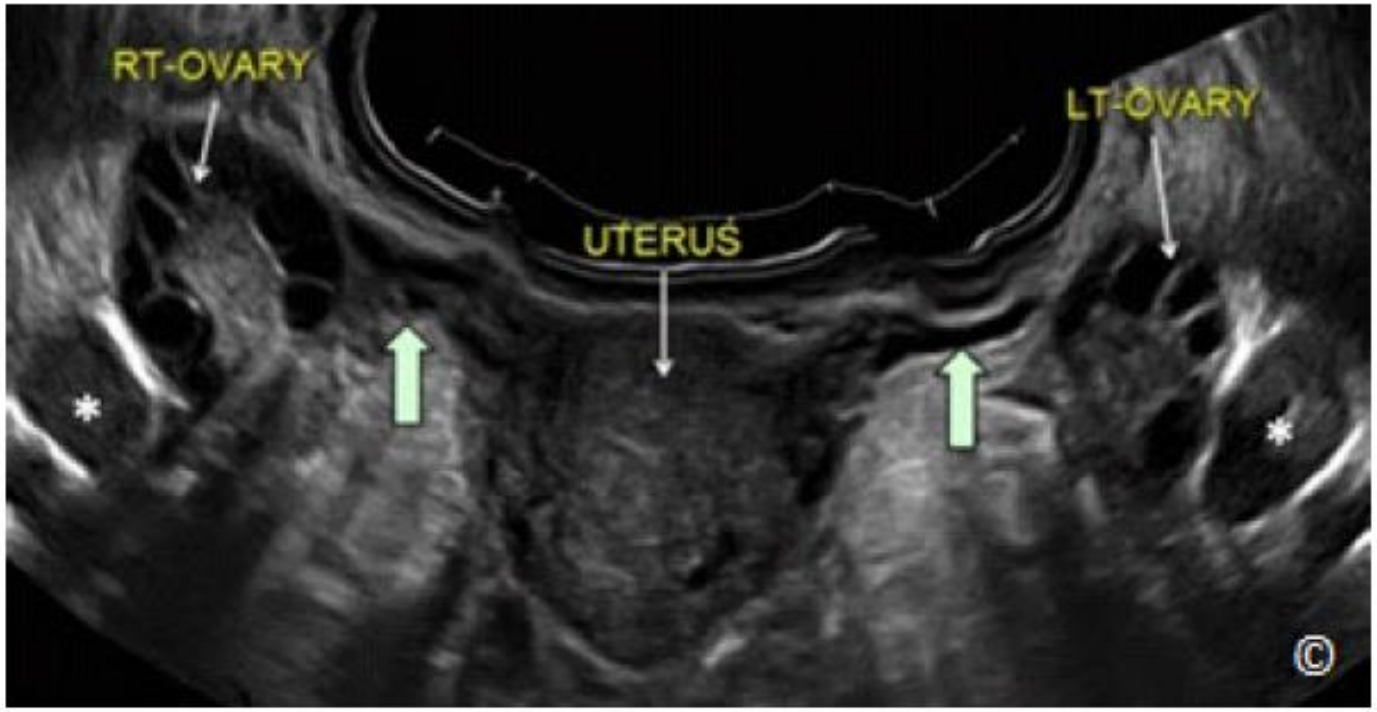

Figure 14.13: Transvaginal ultrasound in extended transverse view of the pelvis showing the uterus (labeled), right and left ovaries (labeled), ovarian ligaments (blue arrows) and the right and left hypogastric veins (asterisks).

MITEN OPTIMOIT UÄ-KUVAN?

Depth (syvyys):

"Suuri kun etsit, pieni kun löydät"

Ja kun löydät kohteen, pienennä anturin kulmaa (**angle**) – kuvan resoluutio paranee

MITEN OPTIMOIT UÄ-KUVAN?

Fokus (paikka ja lukumäärä)

- Focus oikeaan paikkaan!
- Yksi focus parempi kuin kaksi fokusta

Zoom (region of interest ROI)

- Frame rate (kuvien määrä/s) paranee
- Hyvä liikkuvissa kohteissa

MITEN OPTIMOIT UÄ-KUVAN?

Gain:

- Kuva vaalenee
- Pyöritä 2D-nappia, kunnes olet tyytyväinen

Frekvenssi (taajuus):

- Matala fr: hyvä penentraatio, mutta huono resoluutio
- Korkea fr: huono penentraatio, mutta hyvä resoluutio
- Käytä niin korkeaa kuin mahdollista

NORMAALIN KOHDUN KUVANTAMINEN

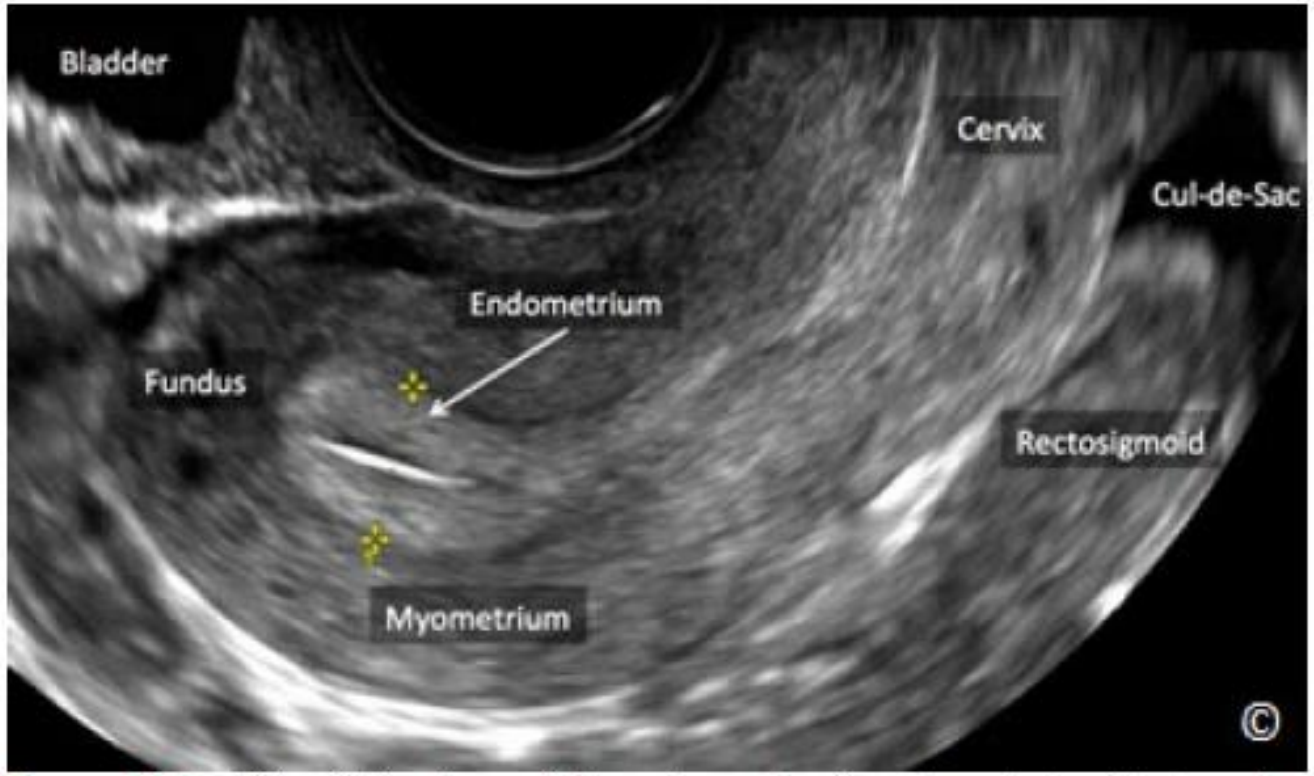

Figure 11.7: Midsagittal plane of the uterus showing the uterine fundus, the myometrium, the endometrium, the cervix, the cul-de-sac, the rectosigmoid and the bladder (all labeled). Note that the myometrium is less echogenic than the endometrium (labeled).

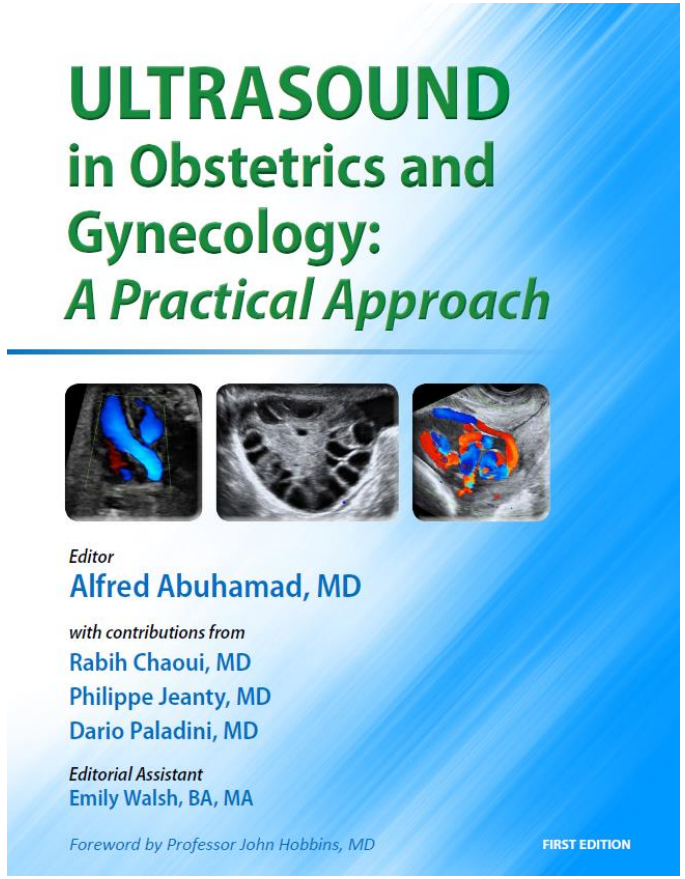

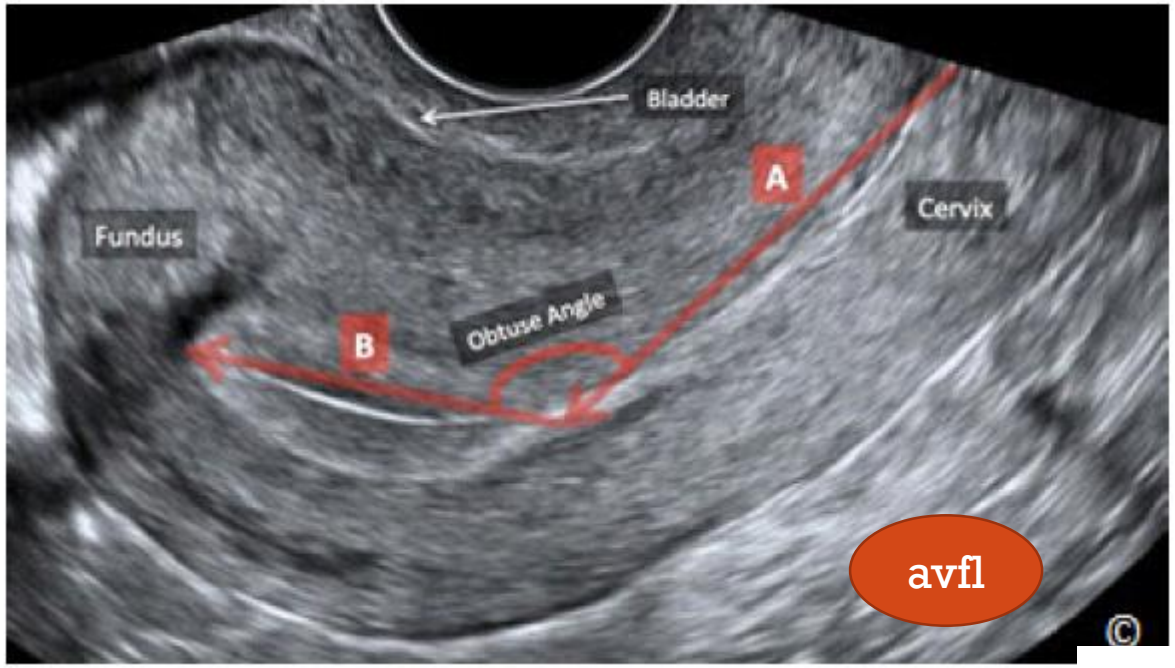

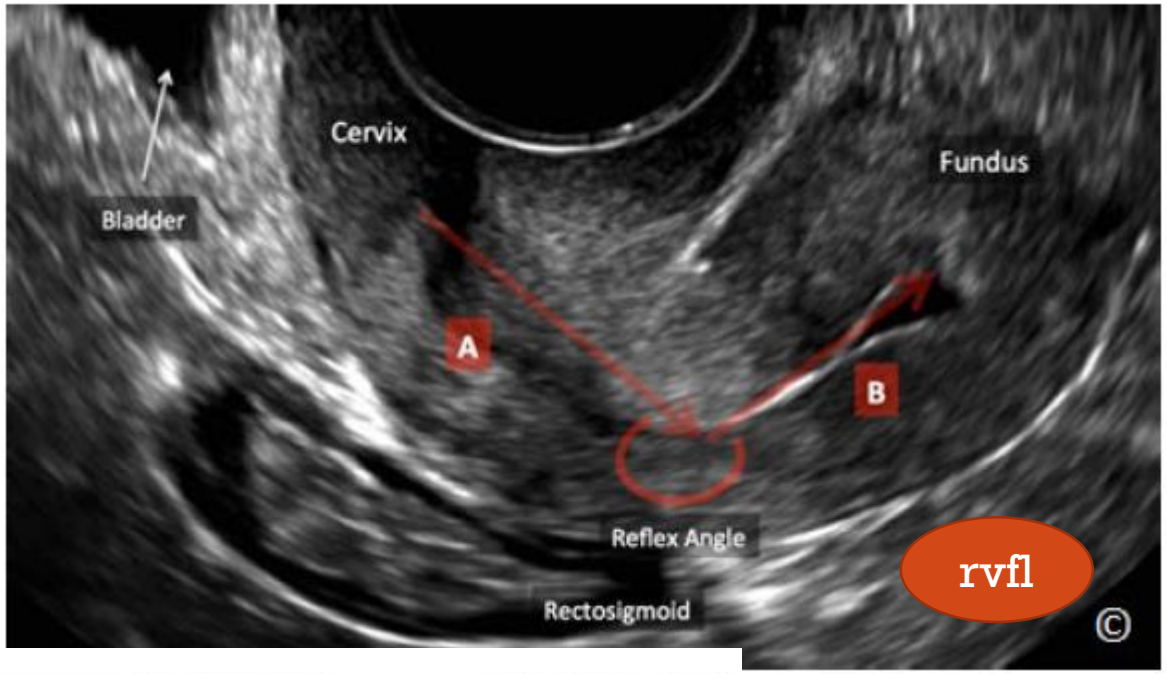

Kohdun asento vaikuttaa kuvantamiseen

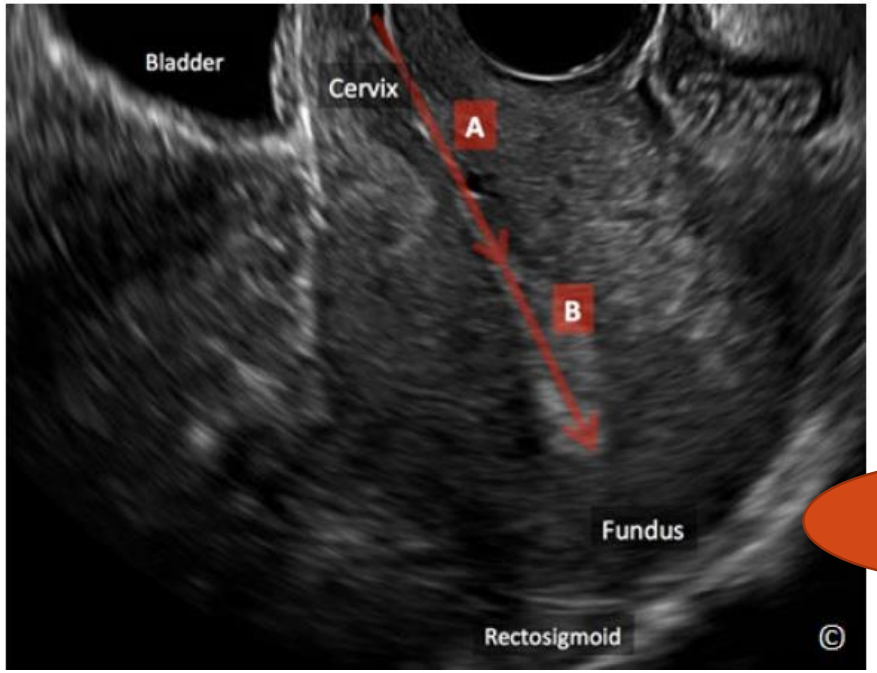

Oikoryhti

Ultrasound Obstet Gynecol 2010; **35**: 103–112
Published online 15 December 2009 in Wiley InterScience (www.interscience.wiley.com). **DOI:** 10.1002/uog.7487

Terms, definitions and measurements to describe the sonographic features of the endometrium and intrauterine lesions: a consensus opinion from the International Endometrial Tumor Analysis (IETA) group

F. P. G. LEONE*, D. TIMMERMAN†, T. BOURNE‡, L. VALENTIN§, E. EPSTEIN¶, S. R. GOLDSTEIN**, H. MARRET††, A. K. PARSONS‡‡, B. GULL§§, O. ISTRE¶¶, W. SEPULVEDA***, E. FERRAZZI††† and T. VAN DEN BOSCH†

Konsensus siitä,miten endometrium ja kohtuontelo kuvannetaan, miten muutokset mitataan ja mitä terminologiaa käytetään.

MITEN ENDOMETRIUM MITATAAN?

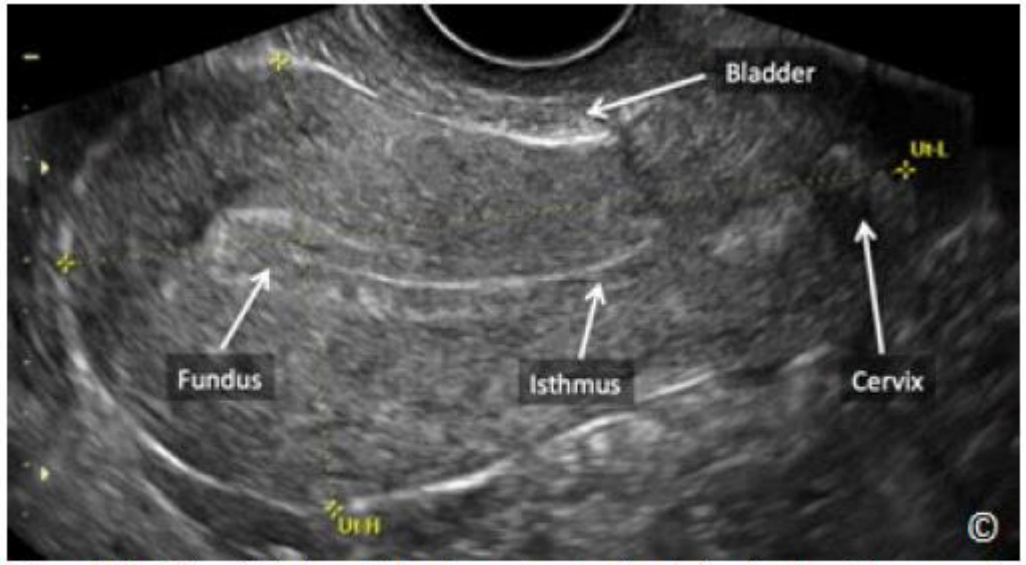

Figure 11.2: Midsagittal plane of the uterus showing the uterine fundus, isthmus, cervix and a collapsed bladder anteriorly (all labeled). In this plane uterine length (Ut-L) and height (Ut-H) are measured.

Figure 11.3: Endometrial thickness measurement. Note that the endometrial thickness is measured at its thickest portion and in a midsagittal plane of the uterus. See text for details.

Laiteasetukset kohdalleen!

- fokus
- angle (kavenna anturin kulmaa, kuvan resoluutio paranee)
- (zoom)

ENDOMETRIUMIN KAIKURAKENNE

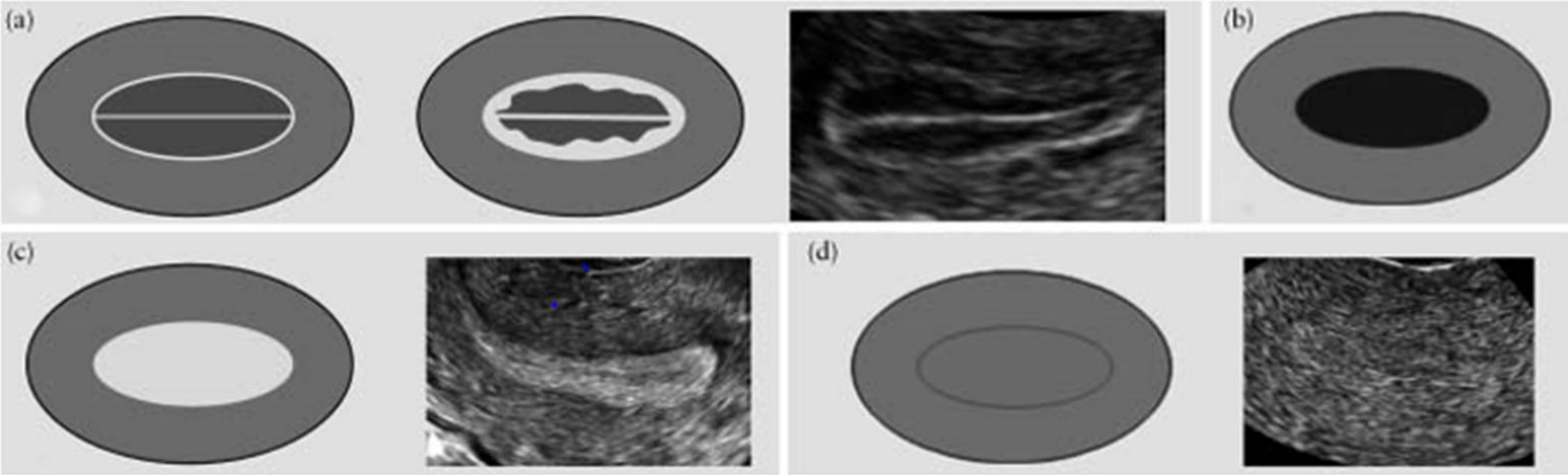

a) triple-layer
b) hypoechogenic
c) hyperechogenic
d) isoechogenic

NORMAALI ENDOMETRIUM SPONTAANISSA KUUKAUTISKIERROSSA

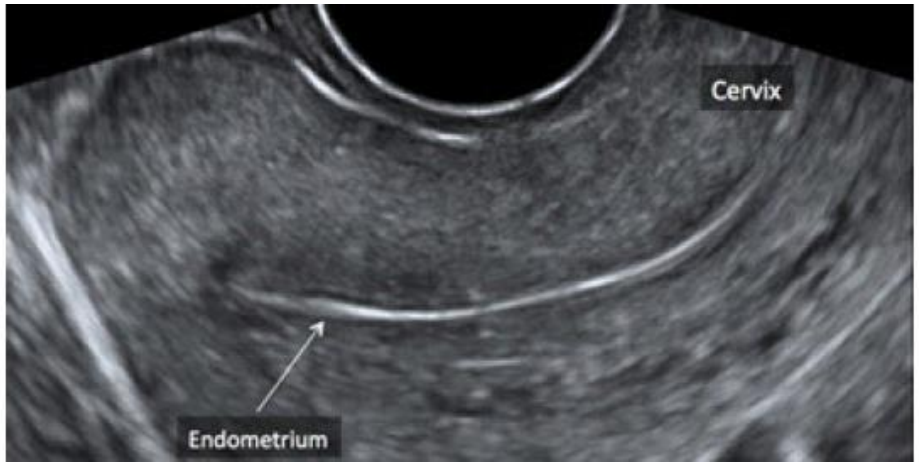

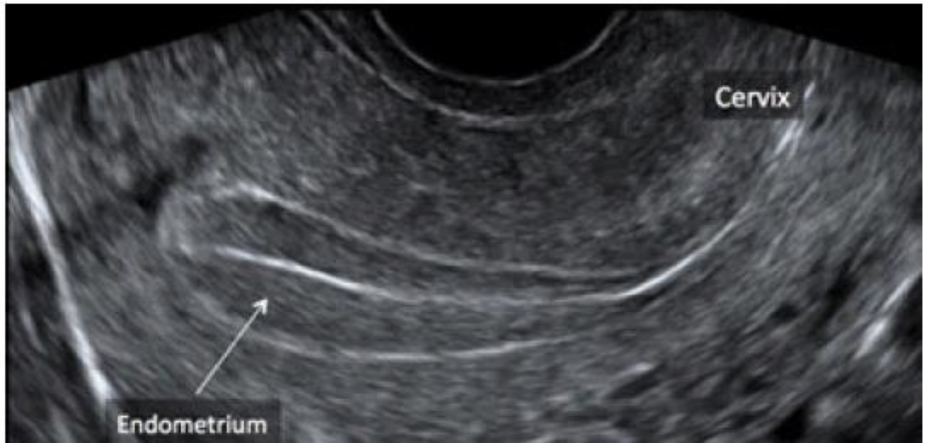

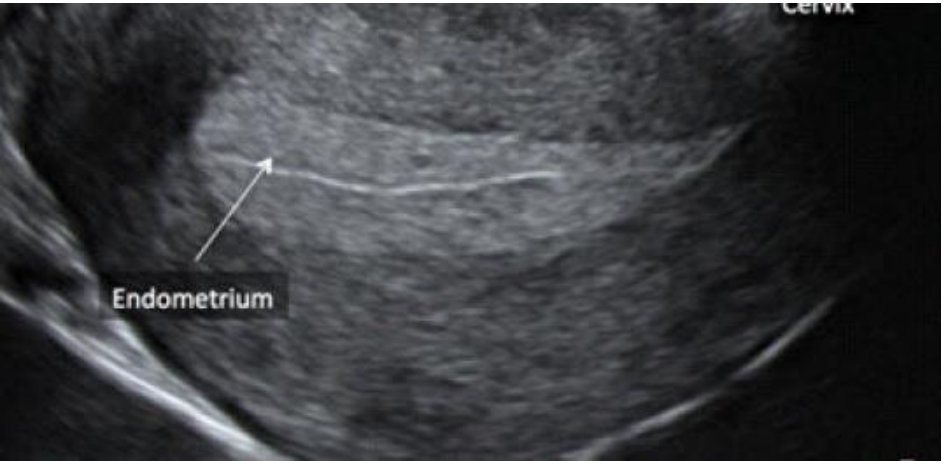

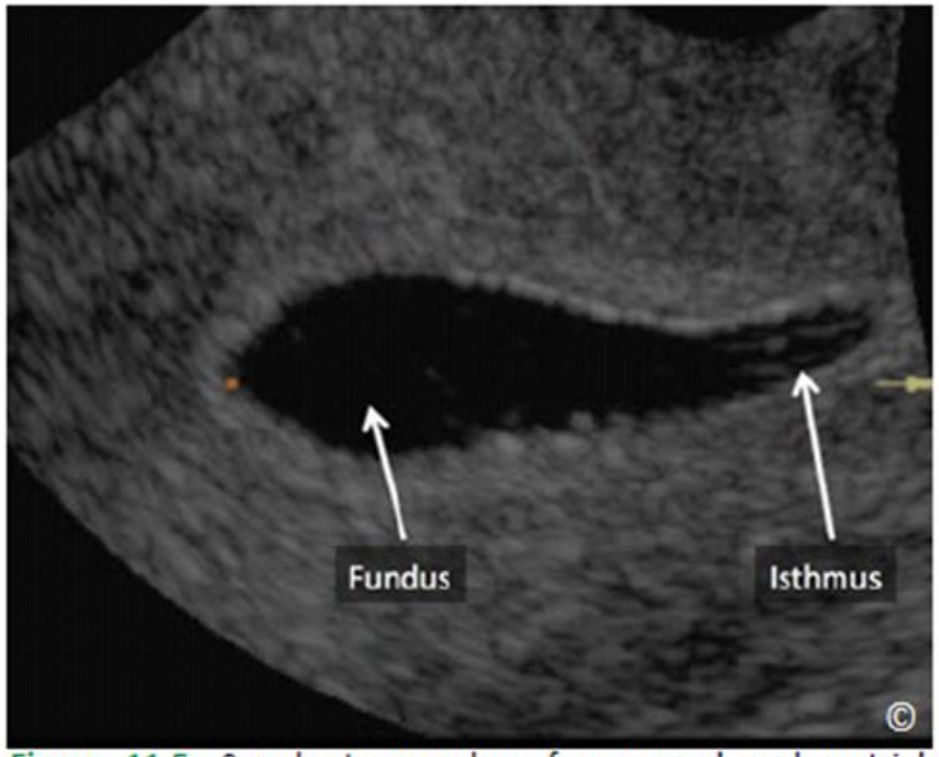

Figure 11.5: Sonohysterography of a normal endometrial cavity showing the fundus and isthmus (labeled).



NORMAALI ENDOMETRIUM POSTMENOPAUSAALISELLA NAISELLA

- Endometriumin raja-arvo 4 mm postmenopaussissa / HRT:n käyttäjillä vuodon jälkeen

Ultrasound Obstet Gynecol 2015; **46**: 284–298
Published online 10 August 2015 in Wiley Online Library (wileyonlinelibrary.com). **DOI:** 10.1002/uog.14806

Terms, definitions and measurements to describe sonographic features of myometrium and uterine masses: a consensus opinion from the Morphological Uterus Sonographic Assessment (MUSA) group

T. VAN DEN BOSCH*#, M. DUEHOLM†#, F. P. G. LEONE‡, L. VALENTIN§, C. K. RASMUSSEN†, A. VOTINO¶, D. VAN SCHOUBROECK*, C. LANDOLFO**, A. J. F. INSTALLÉ††‡‡, S. GUERRIERO§§, C. EXACOUSTOS¶¶, S. GORDTS***, B. BENACERRAF†††, T. D'HOOGHE‡‡‡, B. DE MOOR††‡‡, H. BRÖLMANN§§§, S. GOLDSTEIN¶¶¶, E. EPSTEIN^, T. BOURNE*~ and D. TIMMERMAN*

Konsensus, miten myometrium kuvannetaan, miten muutokset mitataan ja mitä terminologiaa käytetään.

MITÄ MYOMETRIUMISTA PITÄISI LAUSUA?

- KOHDUN KOKO

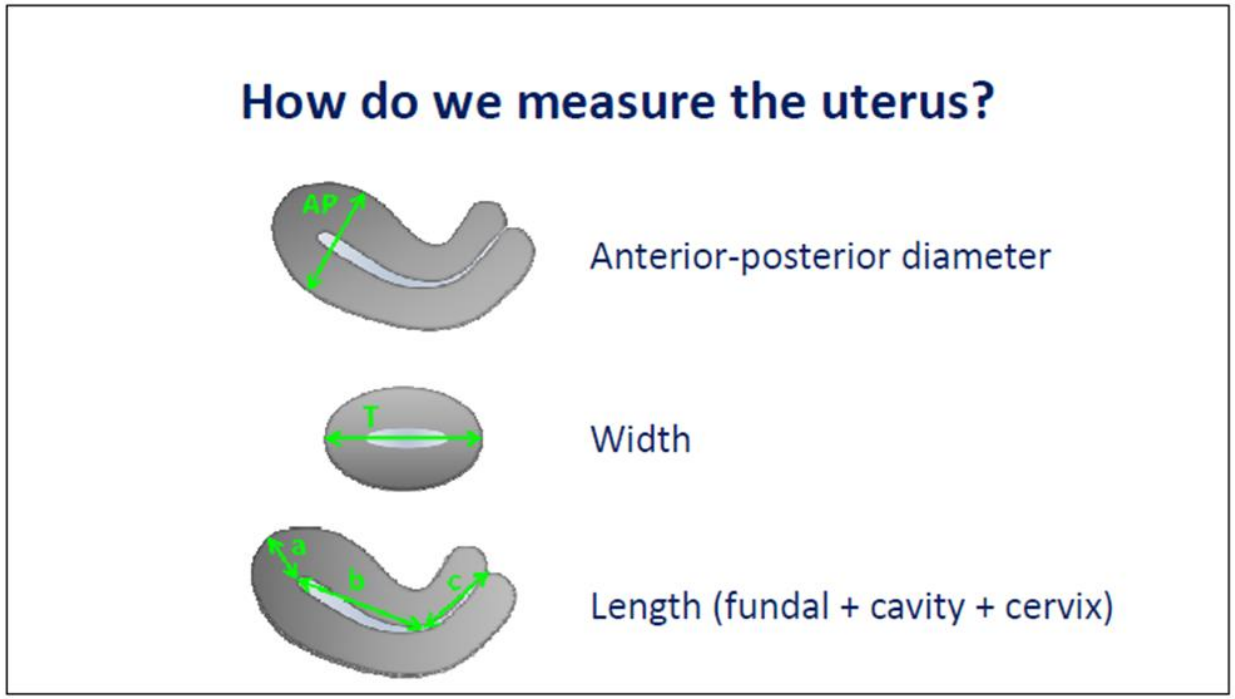

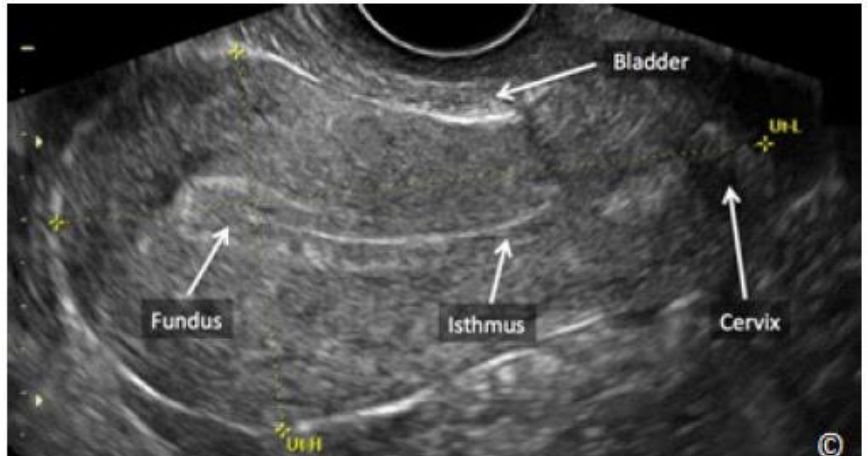

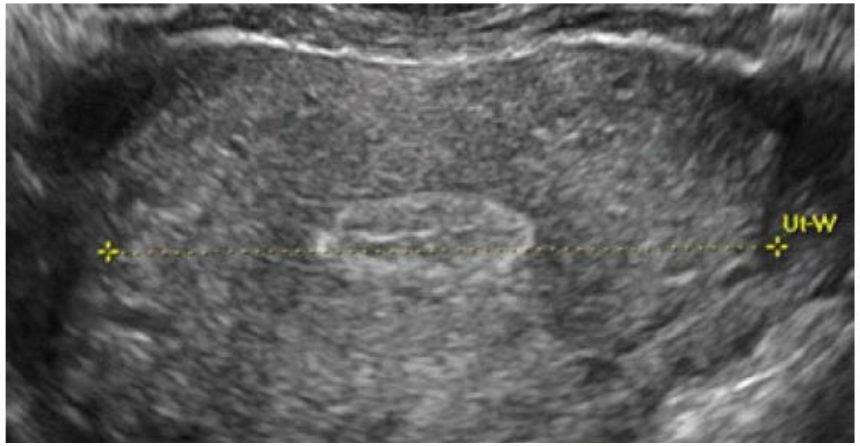

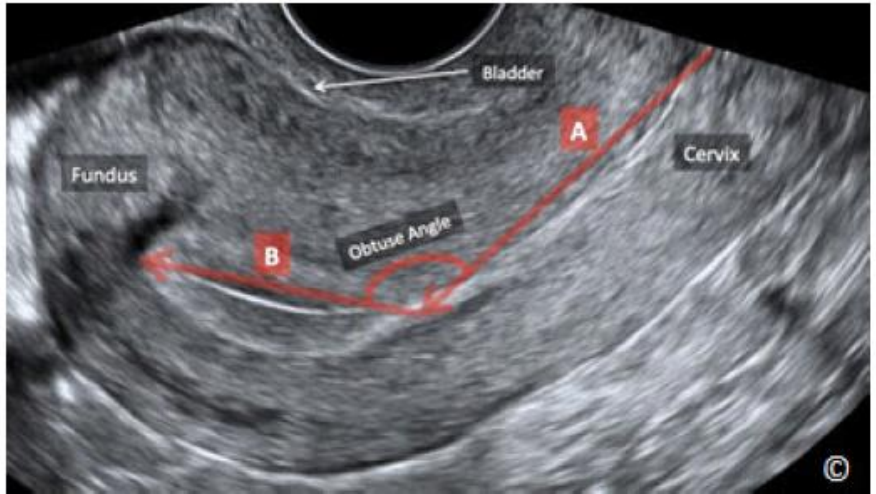

MITÄ MYOMETRIUMISTA PITÄISI LAUSUA?
KOHDUN MUOTO JA SYMMETRIA

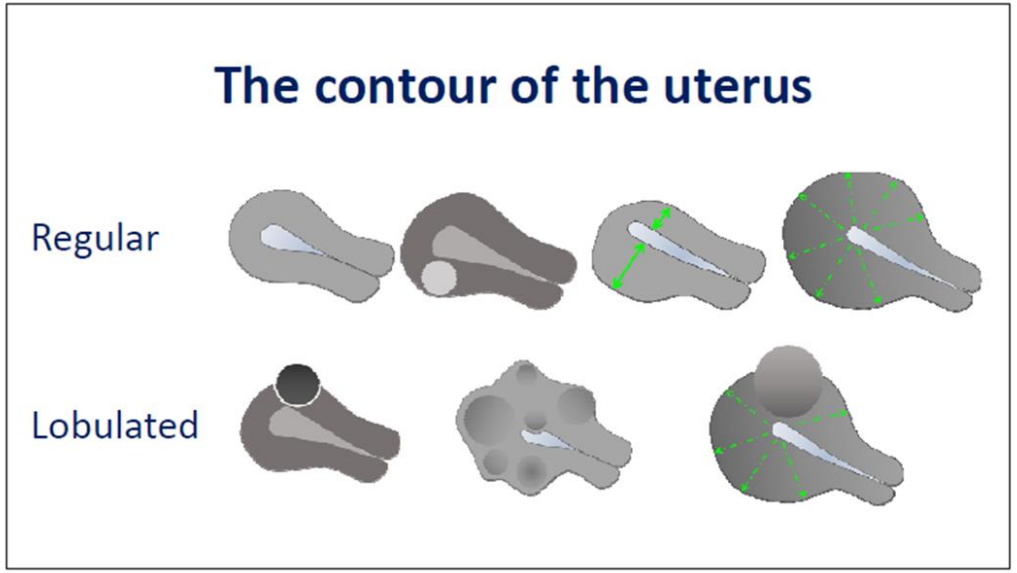

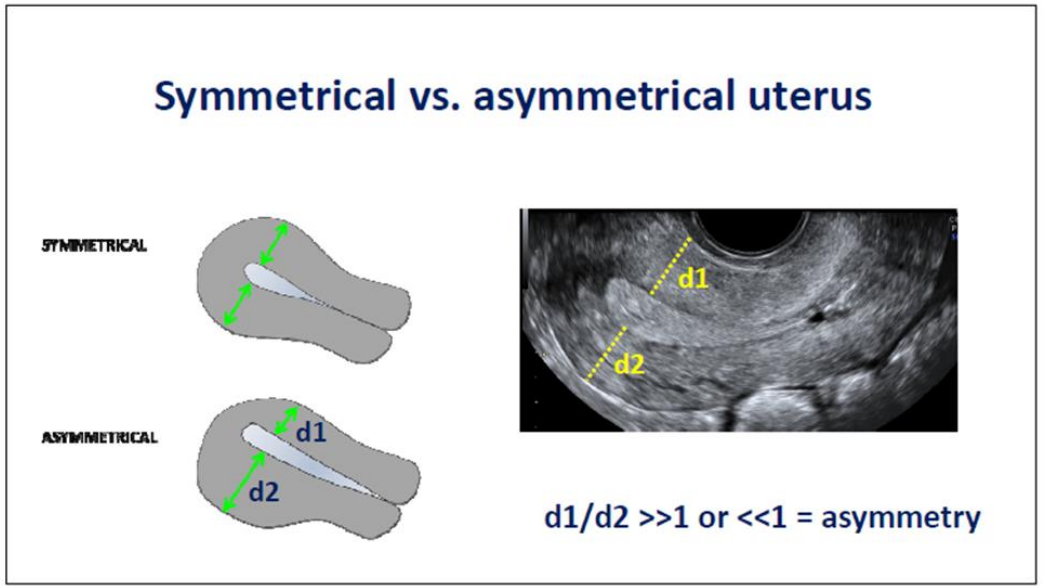

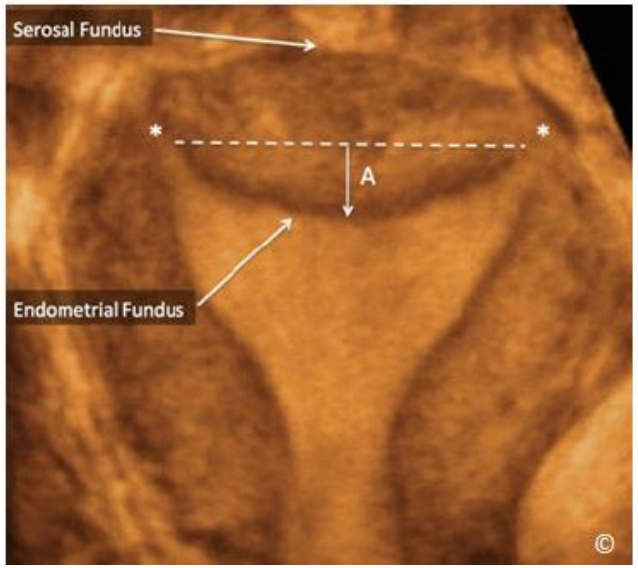

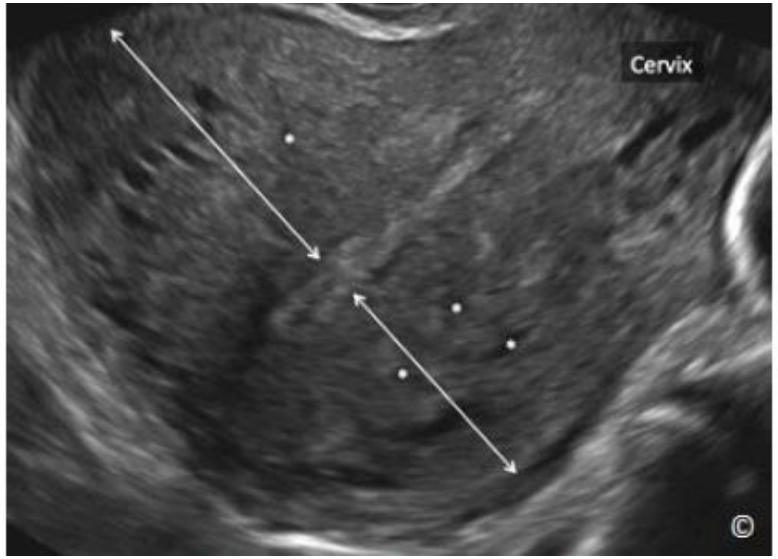

NORMAALI MUNASARJA

Fertiili-ikäisen ovario löytyy aika helposti

Mutta on hankalampaa:

- Nuorilla
- Postmenopaussissa
- kohdunpoiston jälkeen
- Jos suuria myomia / kaikukatveita

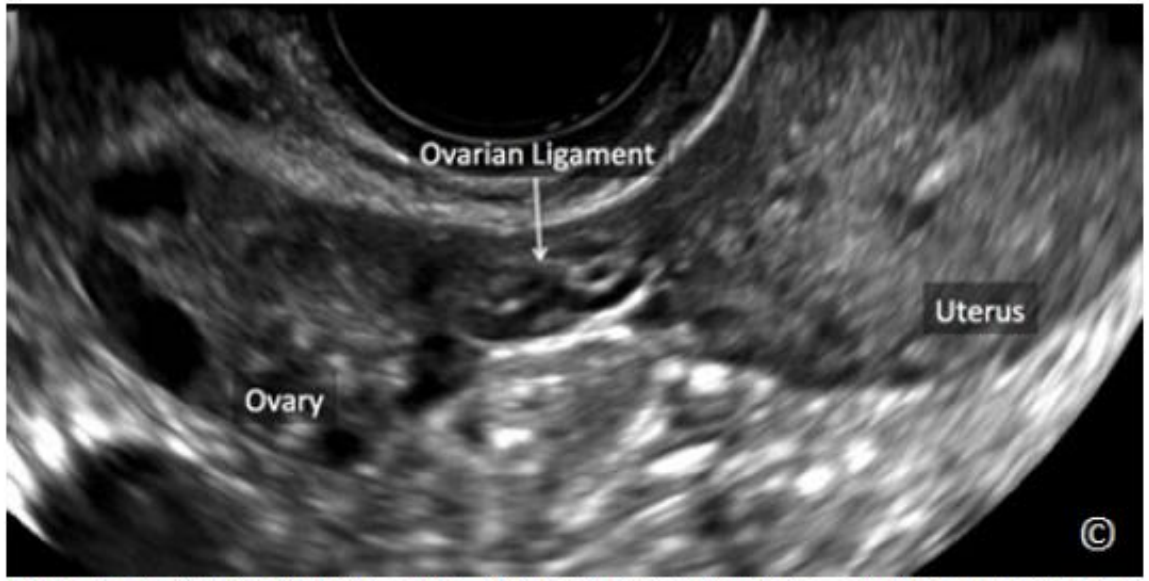

Figure 12.6: Transvaginal ultrasound of the uterus in transverse orientation showing the ovarian ligament and the ovary. Note the relationship between the transverse plane of the uterus (uterus), the ovarian ligament and the ovary (both labeled). By following the ovarian ligament, the ovary can commonly be seen. See text for details.

NORMAALI MUNASARJA FERTIILI-IKÄISELLÄ NAISELLA

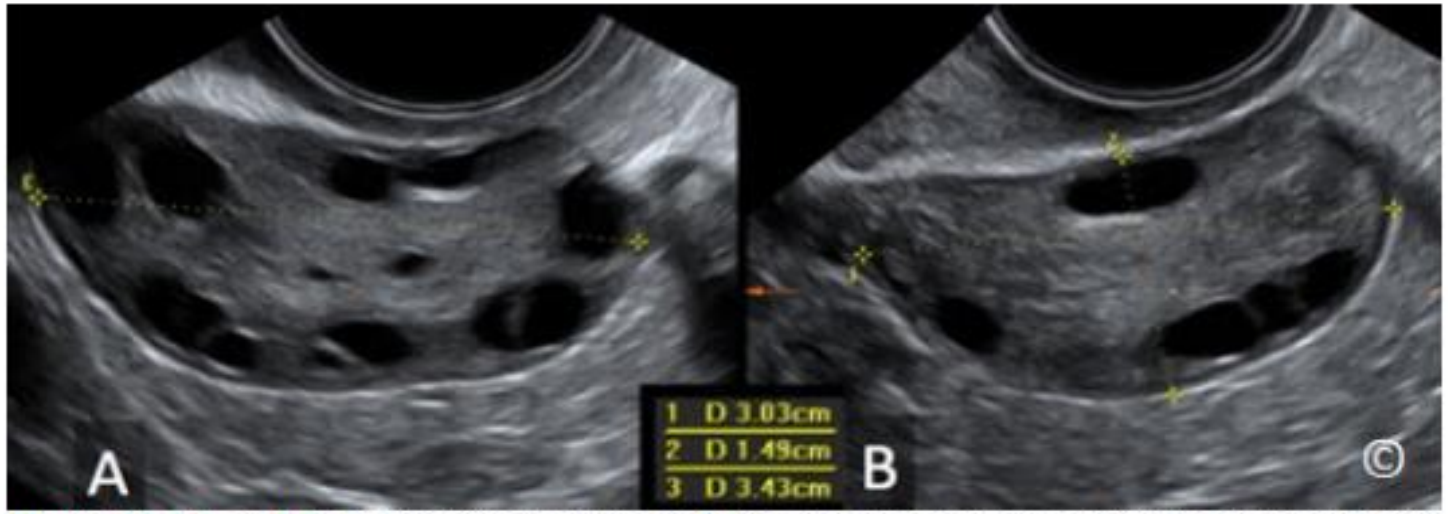

Figure 12.7 A and B: Transvaginal ultrasound showing the measurement of an ovary in its 3 dimensions; length in A and width (measurement 1 on figure B) and depth (measurement 2 on figure B). Figures A and B are orthogonal planes. Image is courtesy of Dr. Bernard Benoit.

Figure 12.31: Transvaginal ultrasound of a polycystic ovary. The ovary is more spherical in shape and has an increased number of follicles that are situated in the periphery of the ovary. Note also the presence of increased stromal echogenicity.

NORMAALI MUNASARJA: CORPUS LUTEUM

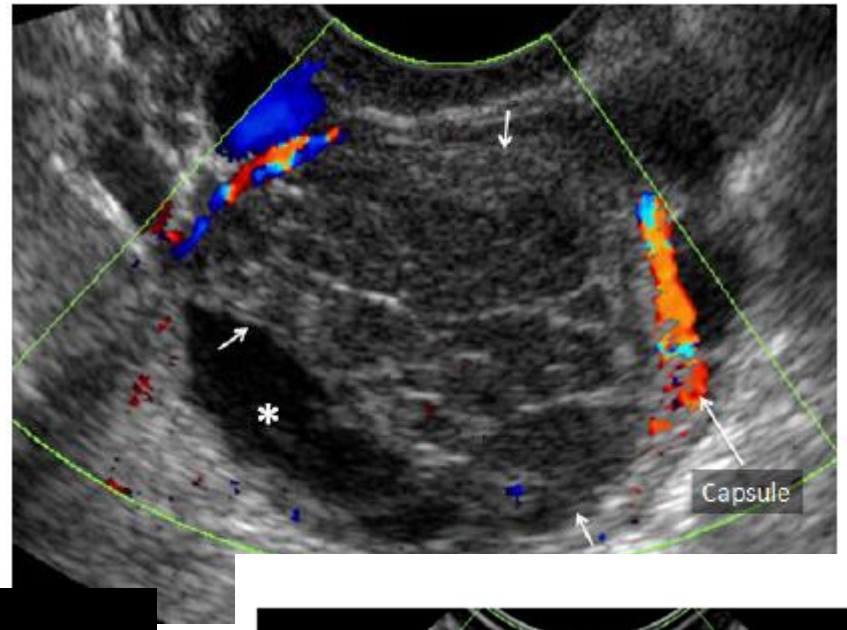

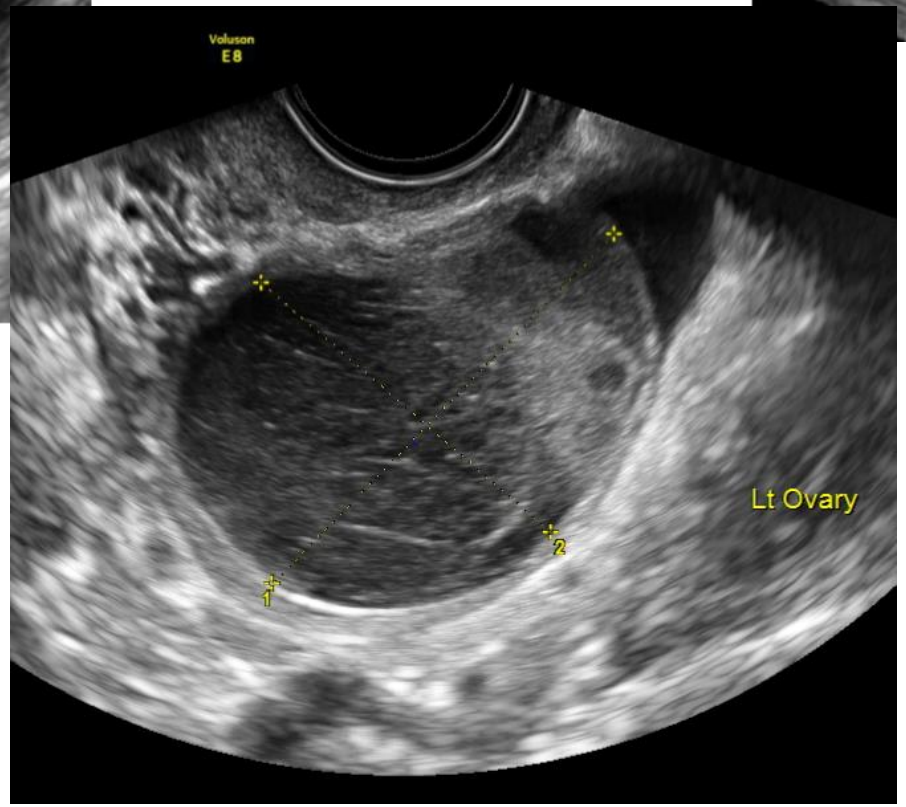

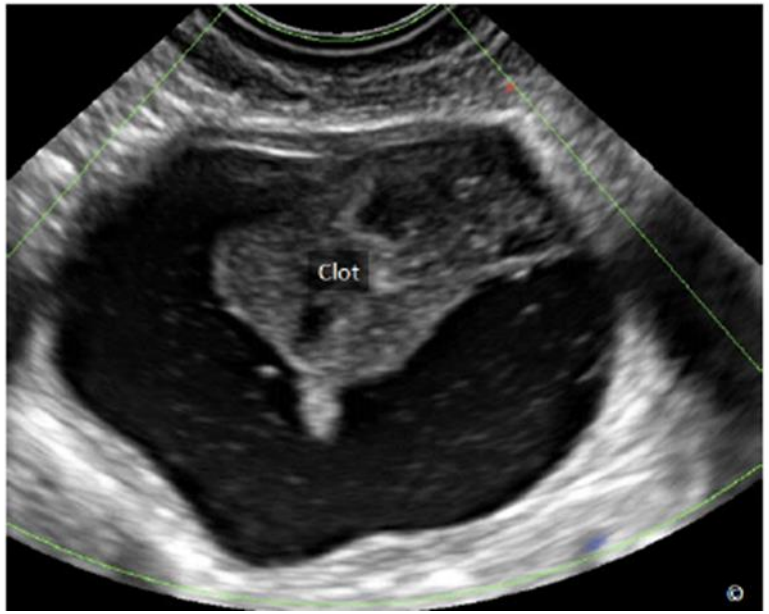

NORMAALI MUNASARJA POSTMENOPAUSSISSA

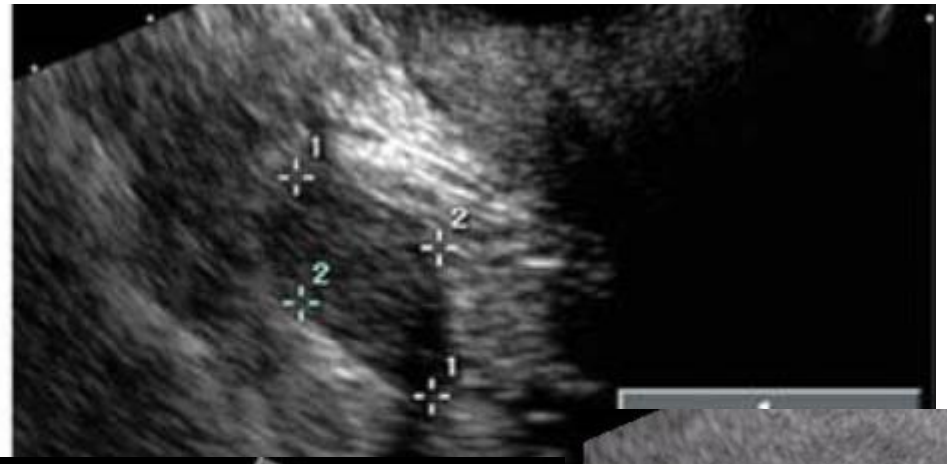

TAKE HOME MESSAGE:

- Orientoidu kuvaan: tiedä missä olet
- Optimoi kuva aina tutkimusta aloittaessasi: fokus, syvyys, kulma, (zoom), gain ja frekvenssi
- Tee uä-tutkimus aina systemaattisesti ja samalla tavalla!
- Vaginaalinen UÄ on dynaaminen tutkimus (käytä sonopalpaatiota)
- Opettele tekemään lausunto systemaattisesti (Apotissa näin tapahtuu)

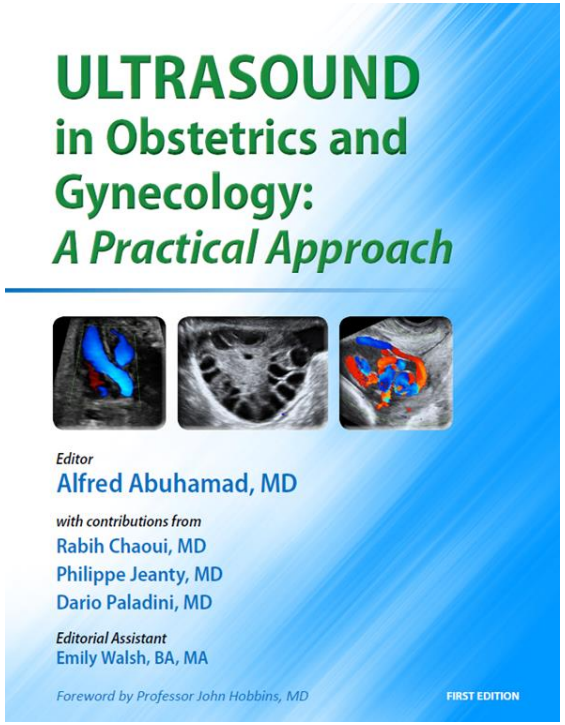

Ultrasound in Obstetrics & Gynecology: A Practical Approach

Download the free-access ebook Ultrasound in Obstetrics & Gynecology: A Practical Approach, which presents a comprehensive review of ultrasound in obstetrics & gynecology and is available in multiple translations.

DOWNLOAD THE FREE EBOOK

isuog.org