Sikiön rakenneseulonnan ajoitus

Juha Räsänen

Synnytys- ja Naistentautien klinikka

Kuopion yliopistollinen sairaala

Table 1 Standards for the 20 week anomaly scan (Royal College of Obstetricians and Gynaecologists)[5]

Scan area	View/structures to visualise
Minimum standard	
Head	Shape, size and internal structures, cavum pellucidum, cerebellum, ventricular size at atrium <10 mm
Spine	Longitudinal and transverse view
Abdomen	Shape and content at level of stomach shape and content at level of kidneys and umbilicus
Renal pelvis	<5 mm anterior–posterior measurement
Diaphragm and bladder	Longitudinal axis abdominal–thoracic appearance
Thorax	At the level of a four-chamber cardiac view
Arms	Three bones and hand (not counting fingers)
Legs	Three bones and foot (not counting toes)
Optimal standard	
Head	Face and lips
Thorax	Cardiac outflow tracts

Table 2 Specifications for the 20-week scan

	Equipment	Timing of scan	Training required	Gestation age at which to scan
RCOG	Modern equipment Not more than 5 years old Should be of modest sophistication	About 20 minutes for the whole investigation, including introduction and documentation	Currently there is no statutory requirement for ultrasound practitioners to receive accredited training Medical staff should be specifically trained to undertake scans	First scan before 15 weeks Detailed scan 20 weeks
NSC	Use of modern equipment (not more than 5 years old) of modest sophistication	–	–	GA assessment before 13 weeks Detailed scan 18–20+6 weeks
NICE	Equipment should be of appropriate standard as outlined by NSC	–	Scan should be done by appropriately trained sonographer	First scan 10–13 weeks Detailed scan 18–20+6 weeks
ARC	–	–	–	For dating before 16 weeks Detailed scan 18–21 weeks
FMF	–	–	–	Dating + nuchal scan 12 weeks Anomaly scan 20–24 weeks

ARC, Antenatal Results and Choices; FMF, Fetal Medicine Foundation; GA, gestation age; NICE, National Institute for Health and Clinical Excellence; NSC, National Screening Committee; RCOG, Royal College of Obstetricians and Gynaecologists.

Feasibility of the second-trimester fetal ultrasound examination in an unselected population at 18, 20 or 22 weeks of pregnancy: a randomized trial

P. Schwärzler, M.-V. Senat, D. Holden, J. P. Bernard, T. Masroor and Y. Ville

Fetal Medicine Unit, St. George's Hospital Medical School, London, UK

Ultrasound Obstet Gynecol 1999;14:92–97

Percentage of anomaly scans completed by gestation

Gestation	18–18+6 weeks	20–20+6 weeks	22–22+6 weeks
% (n) anomaly scan completed	76.3% (306)	90% (371)	88.8% (393)

Table 3 Anomaly scan in the three study groups in terms of need for further ultrasound assessment

	Group 1 (18–18 + 6 weeks; *n* = 401)		*Group 2* (20–20 + 6 weeks; *n* = 412)		*Group 3* (22–22 + 6 weeks; *n* = 393)	
	n	%	*n*	%	*n*	%
Anomaly scan completed	306	76.3	371	90.0	349	88.8
Head/brain views incomplete	16	4.0	9	2.2	4	1.0
Face/profile view incomplete	42	10.5	8	1.9	15	3.8
Thorax/heart views incomplete	81	20.2	28	6.8	21	5.3
Four-chamber view only	74	18.4	12	2.9	16	4.1
Spine/skeletal views incomplete	19	4.7	5	1.2	7	1.8
Other views incomplete	15	3.7	10	2.4	12	3.1
Anomaly scan incomplete	95	23.7	41	10.0	43	10.9
Rescan incomplete*	2	0.5	—	—	—	—
Incorrect sex determination	13	3.2	9	2.2	9	2.3

Table 5 Earliest gestation at which ultrasound diagnoses can reasonably be made at

	Anomaly	11–14 weeks	18–22 weeks
CNS	Anencephaly	✓	
	Holoprosencephaly	✓	
	Corpus callosum agenesis		✓
	Microcephaly		✓
	Hydrocephalus	✓	
	Open spinal defects	✓	
CHEST	Diaphragmatic hernia		✓
	CCAM		✓
CVS	AVSD	✓	
GIT	Gastroschisis	✓	
	Omphalocele	✓	
Urinary system	Hydronephrosis		✓
	Bilateral renal agenesis	✓	
	Severe multicystic or polycystic kidney disease	✓	
	Megacystis	✓	
Neck/face	Cleft lip/palate		✓
	Cystic hygroma	✓	
Skeletal	Arthrogryposis	✓	
	Osteogenesis imperfect	✓	
	Achondroplasia		✓
Extremities	Talipes equinovarus		✓
Other	Ovarian cyst		✓

CNS, central nervous system; CVS, cardiovascular system; GIT, gastrointestrial tract; CCAM, congenital rystic adenomatoid malformation; AVSD, atrioventricular septal defect.

Pathak & Lees, 2009

Table 6 Detection rates for common cardiac conditions at the 20-week scan

	Antenatal detection rate %
Atrio-ventricular septal defect	29[43]
Ventricular septal defect	11.5[45]
Hypoplastic left heart syndrome	54.5[45]
Outflow tract anomalies	21.2[45]

Pathak & Lees, 2009

Proportion of nonchromosomal SI/SII congenital heart defect cases prenatally diagnosed by pregnancy outcome and by country, 2000 to 2005.

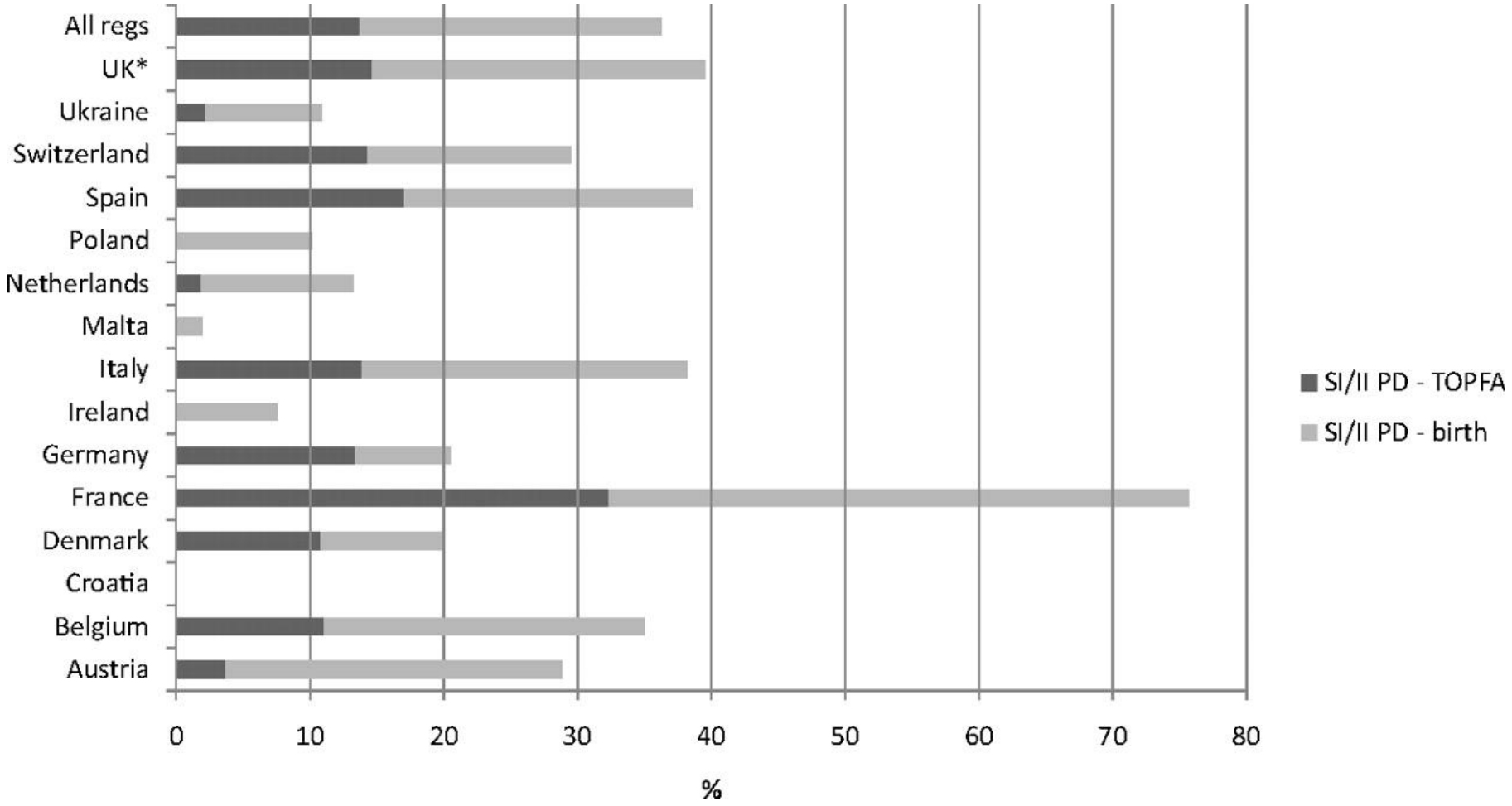

Dolk H et al. Circulation 2011

The evolution of prenatal screening and diagnosis and its impact on an unselected population over an 18-year period

PA Boyd,[a] C Rounding,[a] P Chamberlain,[b] D Wellesley,[c] JJ Kurinczuk[a]

[a] National Perinatal Epidemiology Unit [b] Nuffield Department of Obstetrics and Gynaecology, University of Oxford, Oxford and [c] Princess Anne Hospital, Southampton University Hospitals NHS Trust, Southampton, UK

Correspondence: Dr PA Boyd, National Perinatal Epidemiology Unit (NPEU), University of Oxford, Old Road Campus, Oxford OX3 7LF, UK. Email patricia.boyd@npeu.ox.ac.uk

Accepted 10 April 2012. Published Online 7 June 2012.

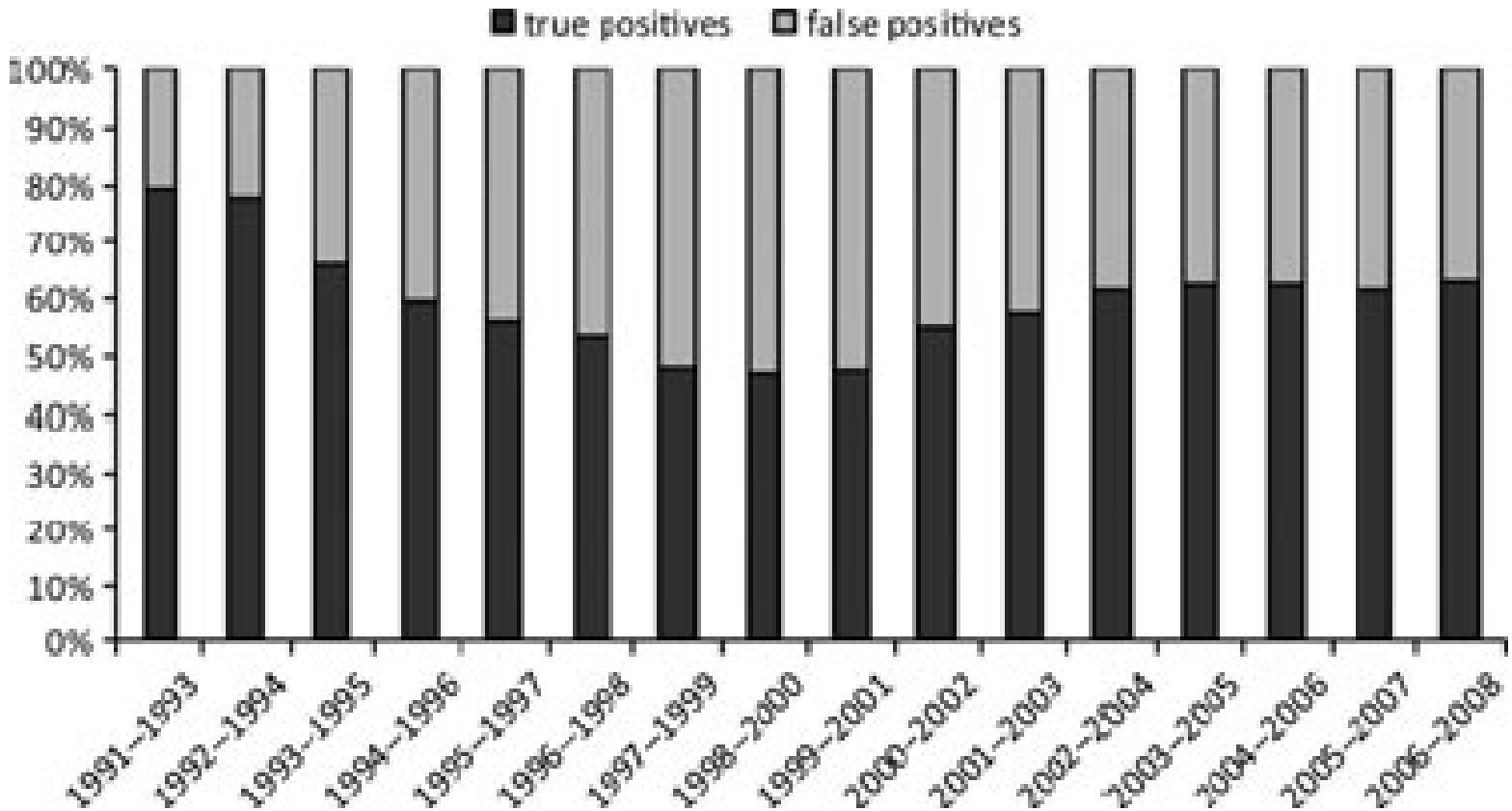

Figure 3. Prenatal suspicion of anomaly—percentage true-positive and false-positive diagnoses (3-year running averages).

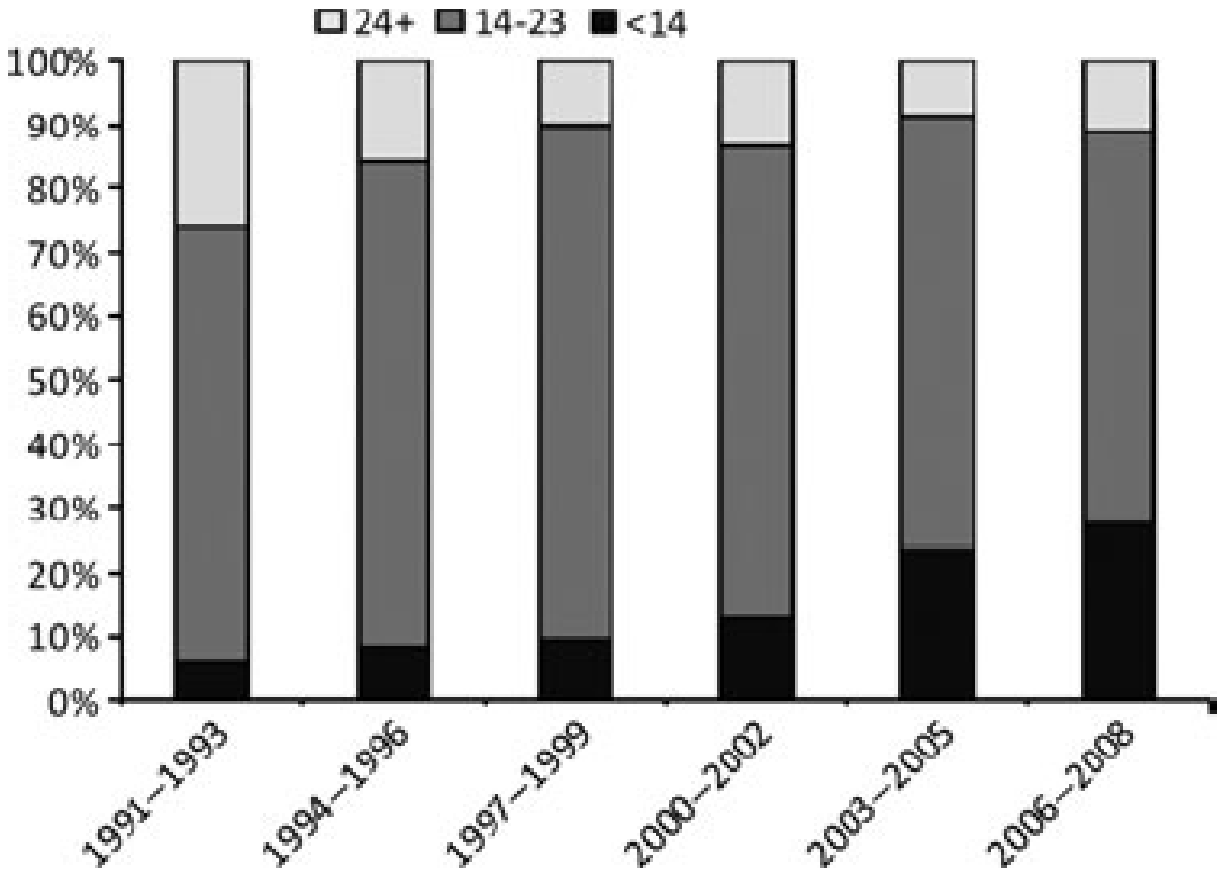

Figure 4. Gestation at prenatal diagnosis 1991–2008 (3-year running averages).

Synnyttäjien painoindeksi (BMI) vuosina 2006−2011

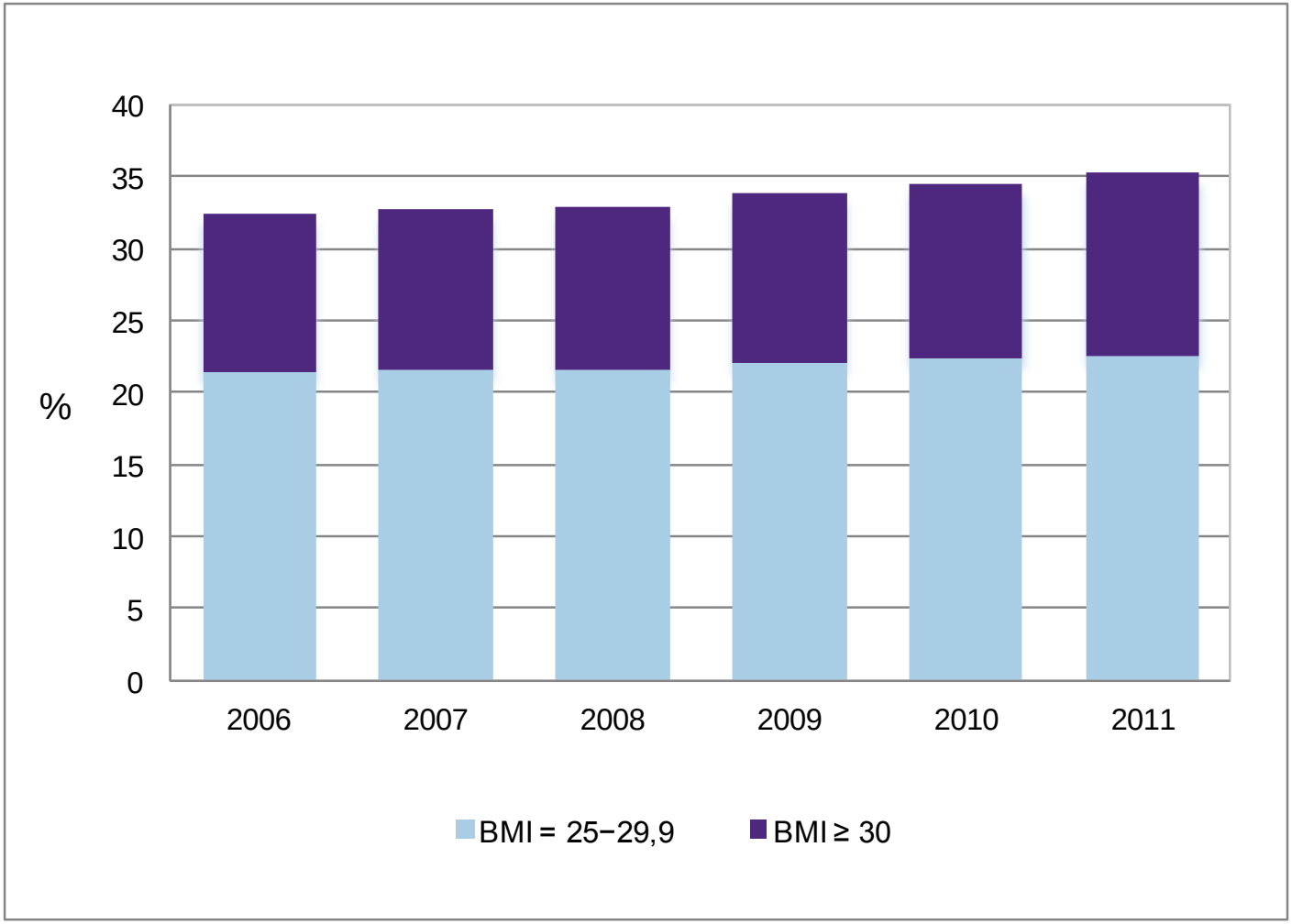

Lähde: THL/ Syntymärekisteri

KYS:n raskaudenkeskeytykset (> 20 rvk) v. 2012

H22+1	**dextrocardia, VSD, HRHS (30v)**
H22+0	**HLHS, DORV, VSD, korvien aplasia, radius hypoplasia (22v)**
H23+3	**DORV, VSD, HLHS, NT 1,4mm (27v)**
H22+1	**Hydrocephalus, lissencephalia (22v)**
H21+0	**Aivoanomalia, oik aivopuoliskon hamartoma (34v)**
H23+0	**Hydronefrosis, rakon ja uretereiden puuttuminen (27v)**
H21+4	**Tanatoforinen dysplasia, NT 1,6mm (30v)**
H22+1	**Trisomia 21, ei NT, 2 soft markeria (30v)**
H21+5	**Trisomia 18, ei NT, rakennepoikk, (28v)**
H20+1	**FragileX täysmutaatio, äidillä esimutaatio, NT 1,3mm (35v)**